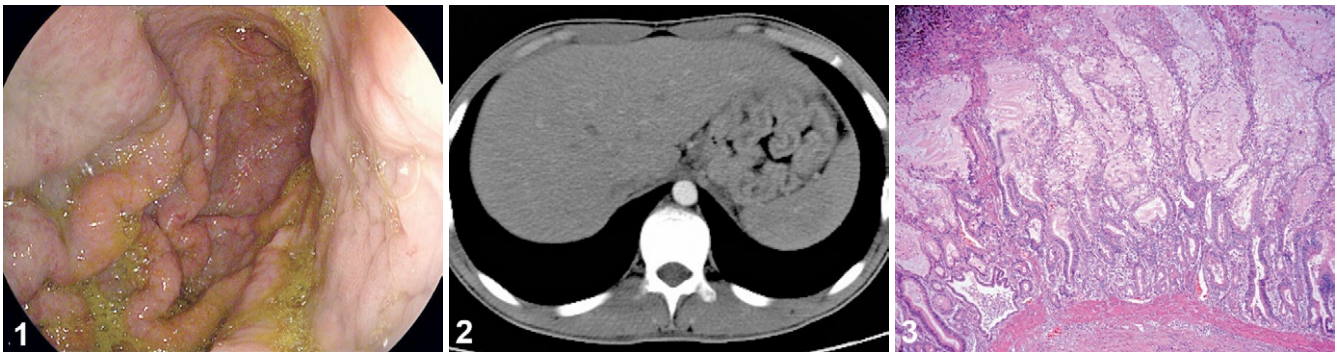


Ménétrier's Disease: a Rare Entity Which Mimicks Gastric Cancer

Ion Bancila¹, Irinel Popescu², Vlad Herlea³, Gabriel Becheanu³, Mona Dumbrava³, Cristian Gheorghe¹

1) Department of Gastroenterology and Hepatology; 2) Department of Surgery and Liver Transplantation; 3) Department of Pathology, Fundeni Clinical Institute, Bucharest, Romania



A 19-year-old male patient was admitted for a one month long history of nausea and postprandial vomiting, anorexia, weight loss (10kg), epigastric pain with radiation in the left upper quadrant. On physical examination, no significant findings were revealed, except for tenderness at palpation of the epigastric region. Laboratory investigations revealed a low serum iron level and hypoalbuminemia. Upper gastrointestinal endoscopy revealed hypertrophic irregular folds of the gastric body, without distension by insufflation and without erosions (Fig. 1). Given the ongoing suspicion of gastric neoplasia, especially lymphoma, a CT scan of the thorax and abdomen was performed, which found only a nonspecific thickening of the gastric wall (Fig. 2) but no thoracic or abdominal lymphadenopathies. The histopathology examination (Fig. 3) showed foveolar hyperplasia, elongated foveolar epithelium, cystically dilated foveolae, loss of oxyntic glands and mild interstitial inflammation, as well as foveolae containing PAS positive neutral mucin. Based on the endoscopic appearance, hypoalbuminemia, pathological aspect and CT scan findings, the diagnosis of Menetrier's disease was established.

Ménétrier's disease is a rare, acquired hypertrophic gastropathy of unknown etiology [1], in several situations associated with *Helicobacter pylori* (HP) or *Cytomegalovirus* (CMV) infection [2, 3]. There are also patients in whom neither HP nor CMV were detected. Although the pathogenesis is not fully understood, an increased epidermal growth factor receptor (EGFR) signaling in the stomach seems to be the pathogenetic mechanism. *In vitro* studies have shown that the administration of transforming growth factor- α (TGF- α) in mice stimulates gastric epithelial growth, inhibits acid production and increases mucin levels [4].

Several treatments have been reported to be beneficial in adult patients, such as HP eradication, prednisone, antibiotics, H₂-blockers, octreotide, non-steroidal anti-inflammatory drugs, but the long-term effects have been usually inconsistent and no clinical

trials have been performed [5]. Recently, cetuximab, a monoclonal antibody against EGFR, has been reported as an effective therapy for the treatment of Ménétrier's disease [6], but the disease may relapse after the halt of therapy; therefore, therapy may have to be continued indefinitely if gastrectomy is declined. At present, the only cure for Ménétrier's disease is a total gastrectomy.

Corresponding author: Ion Bancila, ibancila@yahoo.com

Conflicts of interest: None to declare.

REFERENCES

1. Rich A, Toro TZ, Tanksley J, et al. Distinguishing Menetrier's disease from its mimicks. *Gut* 2010; 59: 1617–1624. doi: [10.1136/gut.2010.220061](https://doi.org/10.1136/gut.2010.220061)
2. Badov D, Lambert JR, Finlay M, Balazs MD. *Helicobacter pylori* as a pathogenic factor in Menetrier's disease. *Am J Gastroenterol* 1998; 93: 1976–1979. doi: [10.1111/j.1572-0241.1998.00347.x](https://doi.org/10.1111/j.1572-0241.1998.00347.x)
3. Setakhr V, Muller G, Hoang P, Lambert AS, Geubel A. Cytomegalovirus-associated protein-losing gastropathy in an immunocompetent adult: a case report. *Acta Gastroenterol Belg* 2007; 70: 296–299.
4. Nomura S, Settle SH, Leys CM, et al. Evidence for repatterning of the gastric fundic epithelium associated with Menetrier's disease and TGF- α overexpression. *Gastroenterology* 2005; 128: 1292–1305. doi: [10.1053/j.gastro.2005.03.019](https://doi.org/10.1053/j.gastro.2005.03.019)
5. Bayerdorfer E, Ritter MM, Hatz R, Brooks W, Ruckdeschel G, Stolte M. Healing of protein losing hypertrophic gastropathy by eradication of *Helicobacter pylori*-is *Helicobacter pylori* a pathogenic factor in Menetrier's disease? *Gut* 1994; 35: 701–704.
6. Fiske WH, Tanksley J, Nam KT, et al. Efficacy of cetuximab in the treatment of Menetrier's disease. *Sci Transl Med* 2009; 1: 8ra18. doi: [10.1126/scitranslmed.3000320](https://doi.org/10.1126/scitranslmed.3000320)