

Anorectal Incontinence. Pathogenesis and Choice of Treatment

Nikolaos Andromanakos¹, Dimitrios Filippou², Panayiotis Skandalakis¹, Vasilios Papadopoulos³, Spiros Rizos², Konstantinos Simopoulos³

1) Department of Propedeutic Surgery, Medical School University of Athens, Laiko General Hospital, Athens. 2) 1st Department of General Surgery, Piraeus General Hospital "Tzaneio", Piraeus-Athens. 3) Department of Surgery, Medical School, University of Thrace, Alexandroupolis, Greece

Abstract

Fecal incontinence represent a complex and multifactorial disorder. Although the condition is widely accepted as belonging to the elderly, it is now becoming apparent that younger adults are also frequently affected. Its incidence is estimated at 2% of the general population, while in the elderly it may increase up to 60%. Despite the considerable advances that have been made in the evaluation of anorectal incontinence during the past decades, the cause of this entity still remains obscure. The patient's history, the physical examination, and specialized investigations are essential for the diagnosis and the selection of the appropriate treatment. In clinical practice the most useful tests are the anorectal manometry, the anal endosonography and the pudendal nerve latency. Complete functional and anatomical assessment of the anorectum, the anal sphincters, and the pelvic floor is mandatory in all patients with fecal incontinence for the appropriate diagnosis and identification of the cause, the type of incontinence and the selection of the appropriate treatment.

Key words

Anorectal incontinence - pelvic floor disorders - anorectal physiology tests - manometry - endosonography - electromyography

Rezumat

Incontinența fecală reprezintă o problemă complexă și multifactorială. Deși, în general, este considerată apanajul vârstnicilor, adulții tineri sunt frecvent afectați. Incidența acesteia este de 2% în populația generală, iar la vârstnici poate crește până la 60%. În ciuda progreselor remarcabile din ultimele decenii în evaluarea incontinenței ano-rectale,

etiologia acesteia este încă nelămurită. Anamneza pacientului, examenul obiectiv și investigațiile de specialitate sunt esențiale pentru diagnostic și alegerea tratamentului. Cele mai folosite teste în practică sunt manometria ano-rectală, endosonografia anală și timpul de latență al nervului rușinos. Evaluarea completă funcțională și anatomică a regiunii ano-rectale, sfincterului anal și a planșeului pelvin este necesară la toți pacienții cu incontinență fecală în vederea obținerii unui diagnostic corect și pentru identificarea etiologiei, tipului de incontinență și alegerea tratamentului corect.

Introduction

Fecal incontinence is a distressing condition, which may turn out to be a devastating disability. The resulting social discomfort is often so intense that it can lead to isolation as severe as that associated with paraplegia. Individuals who have incontinence are hardly willing to go out for a walk, are fearful of making social contact, and frequently become housebound (1). The exact incidence of fecal incontinence is unknown. However, it is more frequent in women than in men; the female-to-male ratio is 8 to 1 (2). Large epidemiological studies estimate its prevalence in approximately 2% of the general population (3). Concerning the elderly, this percentage can be raised up to 60% (4). Despite the fact that it is traditionally considered to affect mainly the elderly, current literature suggests that much younger individuals are frequently affected (5).

The neuromuscular integrity of the pelvic floor and anorectum contributes to the normal anorectal function, continence and defecation. Various diseases influencing stool consistency, rectal sensation, rectal compliance or anal sphincters mechanics, may lead to the evolution of anorectal dysfunction and incontinence. The most common cause of anorectal incontinence is related to sphincter muscle injury during childbirth or anorectal surgery (6).

The strategy towards incontinent patients depends mainly on the specific cause, the extent of the disability as well as the age of the affected individual. However, quality of life is widely accepted as the key issue to which all effort

should be focused (7). The fecal incontinence scoring system, which allows the evaluation of the degree of incontinence as mild, moderate or severe, is a very valuable tool in deciding the appropriate diagnostic tests and treatment (8). However, despite the considerable progress in the evaluation and treatment of urinary incontinence over the past decades, international literature is still unable to answer many substantial issues concerning fecal incontinence (9). Our fragmentary understanding of the pathophysiology and therapeutics of fecal incontinence is reflected in the development of numerous surgical approaches with varying outcomes (10). Thereby, the puzzle that remains to be solved is a challenge for future investigators.

The aim of this article is to review the etiopathophysiology of anorectal incontinence and to underline that an accurate and reliable evaluation of the incontinent patient enables administration of the appropriate treatment and thus constitutes the safest way towards a favourable therapeutic outcome.

Physiology and etiopathogenesis

Both the levator ani muscles and anal sphincters are characterized by a unique state of continuous tonic activity, which is altered in response to different stimuli and conditions (rectal distension, increased intraabdominal pressure) to facilitate the defecation or to reinforce mechanical barriers to prevent leaking of enteric contents (11). The factors which are considered to be responsible for maintaining anal continence and facilitating defecation are: complex function of anal sphincter (high-pressure zone, anorectal angle), anorectal function (anorectal sensation, reflex mechanisms, rectal compliance and capacity), stool volume and stool consistency (12). Consequently, anorectal continence has been defined as the ability to control defecation voluntary, to sense the quality of rectal contents, and to maintain nocturnal control (13).

Many factors might impair the continence mechanisms of the anorectum, thus leading to anorectal dysfunction and incontinence (Table I) (14). Anorectal incontinence may be defined as the continuous or recurrent involuntary or uncontrolled passage of the enteric contents, such as liquid, solid or gases. It may be mild, moderate (loss of control to flatus or/and soiling of the underwear) or severe (deficiency in ability to control stool of normal consistency) (15).

I. Complex anal sphincter mechanism

The complex anal sphincter surrounds the anal canal and consists of striated and visceral smooth muscles: the internal anal sphincter (IAS), the external anal sphincter (EAS), and the puborectalis (PR). The IAS is a smooth muscle, the inner layer of the anal sphincter and is supplied by autonomic nervous system. The EAS is a striated muscle, the external component of the anal sphincter and is

Table I Causative factors of the fecal incontinence

I. Incontinence with normal pelvic floor
A. Diarrheal states
Infectious diarrhea
Inflammatory bowel disease
Short gut syndrome
Laxative abuse
Radiation enteritis
B. Overflow
Impaction
Rectal neoplasms
C. Neurologic conditions
Congenital anomalies (myelomeningocele)
Multiple sclerosis
Dementia, strokes, tabes dorsalis
Neuropathies (e.g. diabetes)
Neoplasms of brain, spinal cord, cauda equina
II. Incontinence with abnormal pelvic floor
A. Congenital anorectal malformations
B. Trauma
Accidental injuries
Anorectal surgery
Obstetrical injury
C. Aging
D. Pelvic floor denervation (idiopathic neurogenic incontinence)
Vaginal delivery
Chronic straining at stool
Rectal prolapse
Descending perineum syndrome

innervated by somatic nerves (16). The deepest part of the EAS is related to the PR, which act as one functional unit (17).

The most important function of the anal sphincter mechanism is the formation of a high-pressure zone inside the anal canal and the anorectal angle. The high-pressure zone constitutes a barrier towards increased rectal pressures and the anorectal continence is maintained as long as anal canal pressure is greater than rectal pressure (18). The IAS was thought to be responsible for 85% of maximal anal resting pressure (19). However, more recent studies attribute maximal anal resting pressure at approximately 55% to the IAS, at 15% to the vascular anal cushions, and at the remaining 30% to the EAS (20). The PR, as a muscular sling, pulls the anorectal junction forward creating the anorectal angle. It is without doubt the most significant mechanism of the anorectal continence (21). However, some studies propose that the anorectal angle plays a limited role in the continence mechanism (22-24). Nevertheless, the importance of the PR muscle in the physiological adequacy of the continence mechanism is documented by the fact that children with congenital absence of both the internal and external anal sphincters retain a high degree of continence (25), and by the fact that the posterior division of the PR for the treatment of constipation is associated with a high degree of incontinence of flatus and liquid stool (26).

Trauma. Traumatic injury of the anal sphincter complex is a significant cause of anorectal incontinence and it is mostly related to anorectal surgery (fistulae, fissures, hemorrhoids, abscesses), obstetrical manipulations, pelvic fractures and impalement (27). The division of the EAS is

likely to cause a mild fecal incontinence in up to 34% of patients, which tends to be more severe in cases of impairment of the innervation of the pelvic floor musculature (28,29). However, the division of the PR muscle is more likely to result to severe incontinence (30). Fecal incontinence following vaginal delivery is the result of a double mechanism, involving both direct sphincter division and nerve injury. Pudendal neuropathy and denervation of the pelvic floor have been detected in up to 60% of patients with incontinence and a concomitant sphincter trauma (31).

Neuropathy. Anorectal incontinence, in approximately 80% of cases, is considered to be idiopathic (neurogenic). It is much more common in women than in men. The affected individuals are characterized by impaired function of the nerves that are distributed to the pelvic floor musculature and the anal sphincter (32). The denervation injury of the pelvic floor muscles is associated with difficult or prolonged childbirth, severe constipation and chronic straining at stool, rectal prolapse, descending perineum syndrome, and advancing age (33). In women, this situation is attributed to the traction of the pudendal nerve or to the compression of the sacral nerves by the descending pelvic floor or by the fetal head (34,35). Important evidence that denervation injury of the pelvic floor is a component of idiopathic (neurogenic) fecal incontinence derives from manometric, electromyographic and pudendal nerve latency studies (36). These studies clearly demonstrate that idiopathic fecal incontinence is characterized by weakness of the pelvic floor and anal canal musculature. However, as prerequisite for idiopathic fecal incontinence is considered, apart from progressive neurogenic muscle weakness, the diminished IAS tone and the reduced rectal compliance (37).

In addition to the above, anorectal incontinence is often related to postmenopausal women. In women, the levator ani muscle shows an unusual sexual dimorphism concerning the size of muscle fibers (38). Thereby, the levator ani muscle may demonstrate a hormone-dependent phenomenon and this feature may be important in understanding the frequency and pathogenesis of pelvic floor disorders in women (39). In the rat, a part of this muscle undergoes involution during the menarche (40). Estrogen receptors have also been identified in the human striated anal sphincter (41). Furthermore, the effect of estrogen on the pelvic floor was recently examined in a preliminary study concerning the effect of hormone replacement therapy on postmenopausal women with fecal incontinence (42).

Patients with dysfunction of the EAS or the PR muscles are aware of the impending danger of leaking or the leaking of gases, liquid or solid stools but they are unable to control the unwanted passage of the enteric contents (43). They have symptoms of urgency, difficulty in postponing evacuation, and incontinence en route to the toilet.

The principal pathophysiological condition of fecal incontinence, in the functional disorder of the anal sphincter complex, is the complete or partial loss of the anal canal high-pressure zone, as well as the increase of the anorectal

angle, which are considered to be significant contributors of the anorectal continence (44).

Internal anal sphincter. IAS dysfunction, which can be the result of physical or functional impairment, may lead to anorectal incontinence. This suggests that IAS plays a significant role in preserving continence (gases and loose stools) (45).

Partial or total internal sphincterotomy is accompanied by an 8-40% postoperative risk of soiling or incontinence concerning gases (46).

Loss of IAS function can be compensated by the proper function of EAS and PR muscles. However, if the voluntary muscles weaken due to age or denervation injury, incontinence may manifest (47,48). The contribution of IAS in maintaining continence is obvious in patients with descending perineum syndrome, in whom anal dilatation leads to severe fecal incontinence (49).

Frequent abnormal episodes of IAS relaxation have been described in 25% of patients with neurogenic fecal incontinence. Frequent and prolonged IAS relaxations are believed to put undue stress on the neurogenically damaged EAS; this may cause occult fecal leakage in these patients (50).

Diabetes mellitus is also a cause of anorectal incontinence in approximately 20% of all patients. The incontinent patients experience impaired IAS tone and diminished resting pressure of the anal canal (51).

Rectal prolapse is associated with incontinence (40-60%) due to IAS dysfunction. Rectal intussusception induces the recto-anal inhibitory reflex (RAIR) leading to maximal relaxation of IAS (52).

Several reports have demonstrated degenerate changes of the IAS in patients with incontinence: including disruption of normal architecture, increased collagen fibril content, abnormally stretched elastic tissue, loss of smooth muscle cells and smooth muscle cell atrophy and necrosis (53-55).

Patients with poor IAS function and low resting pressure commonly experience passive leakage of stool and the need to wear a pad (56).

II. Anorectal function

A. Anorectal sensation and reflex mechanisms

Incontinent patients often report that they have no sense of impending or actual incontinence. Thereby, it is apparent that abnormal anorectal sensation might complicate the neuromuscular damage of the pelvic floor (57).

Rectal sensation is necessary for the normal function of the recto-anal reflex (RAIR and contractile reflex) considered of great significance to the anorectal continence mechanism (58). The sensation of rectal filling is subserved by stretch receptors, which are situated outside the rectum, in the surrounding space of levator ani muscles (59). When rectal sensation is impaired, recto-anal reflex is also impaired. Thereby, rectal distension fails to induce sensation of rectal fullness and response of the EAS or the response of the EAS is delayed (disturbance of the recto-anal reflex) (60). In idiopathic fecal incontinence, diabetes mellitus as well as

a variety of neurological diseases (dementia, cerebrovascular disease, spinal cord lesions, myelomeningocele), a diminished awareness of rectal fullness is observed, which is related to highly sensitive rectal sensory thresholds. In these patients and in the elderly, fecal incontinence or fecal impaction and overflow incontinence occur (61-64).

The sensibility of the anal canal is of great importance to the discrimination of the nature of rectal contents. This phenomenon is called "sampling" and is achieved by the recto-anal reflex (65). Impaired anal sensation causes defective sampling mechanism, which is considered to play a role in the fine adjustment of anal continence and is probably an important factor in the pathogenesis of anorectal incontinence (66).

B. Rectal compliance and capacity

The rectum accommodates passively to distension and intraluminal pressure remains low ($< 100\text{cmH}_2\text{O}$) while the volume increases. The compliance of the rectum ($\Delta V/\Delta P$) can be calculated, providing a measure of the elasticity of the organ (67). Decreased capacity and compliance of the rectum correlate directly with increased stool frequency and decreased continence. These were observed primarily in patients with ulcerative colitis and radiation proctitis (68,69). Also, anorectal function is impaired directly after low anterior resection (rectal stump $< 5\text{cm}$) and coloanal or ileoanal anastomosis (70-72). Moreover, a fibrotic rectum resulting from pelvic sepsis may compromise rectal reservoir function significantly (73). Maximum tolerable volume and rectal compliance are reduced in incontinent patients; these combined abnormalities lead to a low volume high-pressure rectal reservoir, which may contribute to the incontinence in these patients (74).

III. Stool volume and consistency

Anorectal continence can be threatened if large volumes of liquid stool are rapidly introduced into the rectum. In these circumstances, accommodation response of the rectum may be overcome and cortical inhibition may be unavailing. However, urgency can be controlled for only 40-60 seconds by the voluntary EAS complex. This time may be long enough to allow some accommodation. If not, leakage will temporarily relieve the situation (75). Diarrheal states are a common cause of transient or permanent incontinence even if the anal sphincter is normal (76).

Patient assessment

The evaluation of anorectal incontinence (either leakage or urgency) should be focused on determining the cause and the functional status of the patient. This information is crucial in selecting the appropriate therapy, as the outcome highly depends on careful patient selection. A detailed medical record and a careful physical examination contribute mostly in identifying the cause of incontinence and are

believed to be essential in every patient. However, anorectal physiology investigations might be used selectively to confirm the diagnosis and elucidate the anatomical and functional situation of the anorectal apparatus thus assisting decisions for the best treatment (Fig.1) (77).

A detailed medical record will usually determine if the patient's symptoms are due to true or false incontinence, and will document the duration, frequency, severity, and timing of incontinent episodes. Causes of perineal soiling (pseudoincontinence), such as perineal fistula, hemorrhoids, rectal mucosal prolapse, pruritus ani, and anorectal venereal disease, should be excluded. An obstetric medical record as well as information concerning previous anorectal surgery or trauma is obviously important. Furthermore, it is crucial to reveal cases of constipation with chronic straining at stool or rectal prolapse. Perineal pain associated with a neurological manifestation, low back pain or neurological pathology of the lower extremities, particularly of recent onset, is significant and should be documented if suspected. Dietary and medication history should also be noted. Finally, the social impact of incontinence, both at home and work, should be sought (78).

Closing a patient's interview, the clinician should be able to categorize each one in a functional group of either mild, or moderate, or severe incontinence, and to propose any specialized test that might be necessary. Several incontinence scoring systems have been proposed so as: 1) to provide an objective measure of a subject's degree of fecal incontinence, 2) to classify the incontinence in regard to severity of the symptoms, and 3) to assist clinical decision making and post-therapeutic assessment of results (79). As a general rule, low-grade fecal incontinence is treated conservatively, whereas significant incontinence may need an operation.

Physical examination should focus on evidence of incontinence. It consists of perineal inspection, cutaneous anal reflex, digital rectal examination, proctoscopy and rectosigmoidoscopy. Perineal inspection may detect a patulous anus, gaping of the anus on traction of the anal verge, perianal soiling, perianal irritation, scars from previous surgery, prolapsing hemorrhoids, fistula, mucosa prolapse, loss of perineal body as well as obvious muscle defects. The patient is asked to contract the sphincter and to strain. A perineum that bulges downwards or a complete rectal prolapse on straining and lack of contraction on squeeze instructions suggest neurological disorder of the pelvic floor musculature. Next, perianal sensation and the anal reflex are assessed. If cutaneous anal reflex is absent, pudendal neuropathy or cauda equina lesion is suspected. The digital examination of the anus detects fecal impaction, estimates the IAS and EAS function (resting tone and squeeze tone, respectively), and observes the anorectal ring by palpation of the PR. Recto-sigmoidoscopy is always performed to rule out organic diseases, such as rectal neoplasms or proctitis, as a cause of symptoms. Internal rectal prolapse or solitary rectal ulcer may be revealed on proctoscopy. Barium enema or colonoscopy may be indicated in selected cases accor-

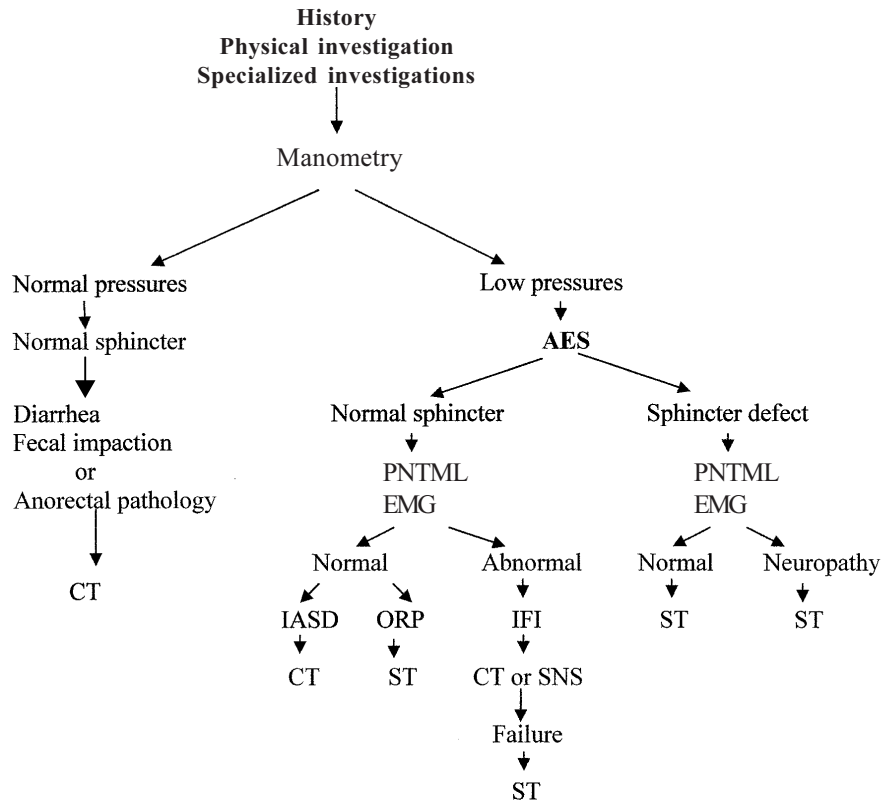


Fig.1 Anorectal incontinence: assessment and treatment selection. AES: anal endosonography, PNTML: pudendal nerve terminal motor latency, EMG: electromyography, IASD: internal anal sphincter dysfunction, ORP: occult rectal prolapse, IFI: idiopathic (neurogenic) fecal incontinence, CT: conservative treatment (diet, antidiarrheal medicines, biofeedback), ST: surgical treatment (sphincter repair, postanal repair, anterior pelvic floor repair), SNS: sacral nerve stimulation.

ding to medical record and findings of physical examination (80).

Specialized investigations complete the clinical evaluation and are useful as they provide an objective assessment of the incontinent patients and document an accurate diagnosis concerning the cause of the anorectal incontinence. The accurate assessment of the clinical problem is considered crucial for the decision of the most appropriate treatment and the achievement of the most favourable outcome. Studies of anorectal physiology include anorectal manometry, anal endosonography (AES), nerve stimulation techniques (pudendal nerve conduction and spinal stimulation), electromyography (EMG), defecography, endoluminal magnetic resonance imaging (MRI), saline continence test, and balloon-retaining test (81). In clinical practice, anorectal manometry, AES and pudendal nerve latency have been proved to be the most useful tests in diagnosis and after treatment. However, the need for each one of these tests will largely depend on medical records, symptoms, and physical examination, and can vary between patients (82).

1. Anorectal manometry

Anorectal manometry is not a single test; it consists of a series of measurements assessing anal sphincter function,

rectal sensation, recto-anal reflexes, and rectal compliance. This is one of the first tests for anorectal function and it constitutes the first-line investigation for incontinence. Various techniques have been used in the study of anorectal manometry as fluid-filled open-tipped catheters, closed multiple balloon systems and microtransducers (83).

Anal manometry is used to establish the presence and extent of weakness of the pelvic floor sphincter muscles, allowing an objective measure of resting and squeeze pressure. It additionally assesses the length of the high-pressure zone. Anorectal incontinence exhibits a low anal sphincter resting tone. The pressure profile during squeeze is compared with the resting profile. If the voluntary squeeze effort results in a normal or increased pressure, the main deficiency resides in the IAS, as might be seen in diabetes mellitus or a previous anal dilatation, previous sphincterotomy or an internal prolapse. If the squeeze effort fails to raise the anal sphincter pressure considerably, additional compromise of the external sphincter must be assumed. Squeeze pressure is lower in weakness of the external sphincter due to trauma or neurologic deficit. Resting pressure is lower in traumatic sphincter injury, rectal prolapse, pudendal nerve traction injury, spinal or cauda equina injury, chronic inflammatory bowel disease, chronic radiation proctitis, and ongoing age. High-pressure zone is

often very short in incontinent patients; these patients can be helped by procedures like post-anal repair. Nevertheless, while manometry can differentiate lower anal pressures from normal values, it cannot distinguish between causes of diminished pressure such as anal sphincter defect due to trauma or impaired innervation of the musculature of the pelvic floor and EAS (84).

2. Anal endosonography (AES)

This is the test of choice, which provides information about the integrity of the IAS and EAS and detects sphincteric defects with an accuracy of 90 to 100 percent (85).

A rotating endoprobe with a 10-mm MHz transducer allows 360 degrees evaluation of the anal canal. The examination does not require any preparation or sedation and is normally well tolerated by the patient. AES can evaluate apart from the anatomy of anal sphincters, the anorectal angle and the PR function (86).

AES is a valuable tool in planning restorative surgery as well an effective technique in assessing results after sphincter repair. It is more accurate and better tolerated than needle electromyography or manometry in mapping the EAS. This explains why AES has almost replaced the more invasive technique of EMG. However, EMG may detect functional abnormalities in incontinent patients with normal anal sphincters on AES; thus the two techniques are complementary and not mutually exclusive (87).

3. Pudendal nerve terminal motor latency (PNTML)

PNTML is a useful test in the anorectal physiology study. The pudendal nerves collect stimuli from the lateral wall of the rectum and refer to the level of the ischial spine. The response of the EAS muscle is recognized by the recording electrodes at the base of the finger. The delay between nerve stimulation and muscle response recording is called nerve latency. The normal value of PNTML is < 2.3msec, and prolongation indicates damage of pudendal nerve (88). Prolongation of PNTML is considered to be a hallmark of idiopathic fecal incontinence (89). However, this examination assesses the neurological status of the sphincter and is useful in patients who are candidates for sphincter repair. It has been demonstrated that the presence of pudendal neuropathy restricts the efficacy of sphincter repair to only 10%. In contrast, when pudendal nerve is intact, the chance of success is raised up to 80% (90).

4. Electromyography (EMG)

EMG of striated pelvic floor and anal sphincter muscles can be performed using a needle electrode, a surface electrode on the perianal skin, or an anal plug. It provides an assessment of the neuromuscular integrity of the anal canal by recording the motor unit action potentials generated by the EAS and PR muscle fibers at rest, during voluntary contraction, and in response to various reflexes (91). Special neurophysiological techniques investigate the pattern and extent of injury in the various pelvic compartments in incontinent patients. The main purposes of the EMG are: to identify areas of sphincter injury by mapping the sphincter, to determine whether the muscle contracts or relaxes, and

to identify denervation-reinnervation potentials that are indicative of nerve injury (92). However, although the concentric-needle EMG has long been used for the assessment of disorders of anal sphincters, the most convenient technique of AES has largely replaced EMG in the current assessment of the anal sphincter anatomy (87). Surface EMG appears to preserve a definite role in the evaluation of sphincter function and in the use of biofeedback training. This test may be used to provide a visual or audible signal during biofeedback pelvic floor retraining (93).

5. Defecography

To perform this examination, the semi-solid barium paste is injected into the rectum. During radiologic examination, the patient is seated on a commode. Profile radiographs are taken at rest, squeeze and during straining, while lateral fluoroscopic images are preceded. The examination is not routinely indicated in patients with incontinence, but it provides information about the presence of anatomical abnormalities, such as intussusception, rectal prolapse, rectocele and perineal descent in selected cases. Patients with incontinence may also demonstrate inability to hold the rectal contrast. In these patients, the anorectal angle is significantly larger than in normal subjects, particularly at rest. Moreover, other patients may demonstrate a poorly distensible rectum suggesting a capacity abnormality (94).

6. Endoluminal magnetic resonance imaging (MRI)

Endoluminal MRI allows detailed visualization of the normal anatomy and pathologic conditions of the anal sphincter. It is superior to endoluminal ultrasonography and can easily identify atrophy of the EAS, which suggests a negative outcome after sphincter repair. The diagnosis of EAS atrophy by ultrasound is not yet resolved, and this remains an important indication for endoanal MRI. However, it seems that IAS is better evaluated by AES (95).

7. Anal mucosal electrosensitivity and thermal sensitivity

Anal mucosal electrosensitivity technique is a method, which may assess the anal sensation. It uses an electrode probe introduced into the anal canal (upper, middle and lower). Consequently, the current is gradually increased until the patient reports a tingling of sensation (threshold) (96). Patients with idiopathic fecal incontinence have an increased threshold of anal sensation or inability of anal sensation in the electrostimulation (97).

Thermal sensitivity technique is another method, which assesses the thermal threshold of the anal canal. A 1cm probe is introduced into the anal canal, through which water of various temperature can be pumped. The anal canal is highly sensitive to temperature change, and incontinent patients are significantly less sensitive than controls (98).

Conclusion

In conclusion, fecal incontinence is a severe disability with undetermined incidence. There are many causative

factors, which may generally be divided into neurological and local. The assessment of patients with fecal incontinence is achieved by medical records, physical examination, and specialized tests. A careful history along with the physical examination of the patients with symptoms of flatus or stool incontinence and the subsequent use of incontinence scoring systems enable the proposal of specialized investigations for each patient. These investigations offer an accurate causative diagnosis of anorectal incontinence and thus contribute to the selection of the appropriate treatment and the achievement of the most favourable outcome. In clinical practice, anorectal manometry, AES, and PNTML have been proved to be the most useful tests for diagnosis settlement and treatment selection. Endoanal ultrasound is one of the first tests to show internal sphincter degeneration and tears of the internal or external sphincters. However, the diagnosis of EAS atrophy on ultrasound is not yet resolved; this still remains an important indication for endoanal MRI. Anorectal manometry is the first-line investigation. It is used to assess the sphincter function by documentation of resting and maximal squeeze pressures as well as rectal sensation and rectal compliance. PNTML or EMG helps to access the diagnosis of neuropathic incontinence. In addition, PNTML is significant in demonstrating sphincter neuropathy, which may reduce the chance of a favourable result after sphincter repair.

References

- Swash M. Neurology of the sphincters. *Clin Exp Neurol* 1987;23:1-14
- Johanson JF, Lafferty J. Epidemiology of fecal incontinence: the silent affliction. *Am J Gastroenterol* 1996;91:33-36
- Nelson R, Norton N, Cautley E et al. Community-based prevalence of anal incontinence. *JAMA* 1995;274:559-561
- Mavrantonis C, Wexner SD. A clinical approach to fecal incontinence. *J Clin Gastroenterol* 1998;27:108-121
- Henry MM. Pathogenesis and management of fecal incontinence in the adult. *Gastroenterol Clin North Am* 1987;16:35-45
- Toglia MR. Pathophysiology of anorectal dysfunction. *Obstet Gynecol Clin North Am* 1998;25:771-781
- Baig MK, Wexner SD. Factors predictive of outcome after surgery for faecal incontinence. *Br J Surg* 2000;87:1316-1330
- Shelton AA, Madoff RD. Defining anal incontinence: Establishing a uniform continence scale. *Semin Colon Rectal Surg* 1997;8:54-60
- Wall LL. The muscles of the pelvic floor. *Clin Obstet Gynecol* 1993;36:910-925
- Osterberg A, Edebol Eeg-Olofsson K, Graf W. Results of surgical treatment for faecal incontinence. *Br J Surg* 2000;87:1546-1552
- Porter NH. A physiological study of the pelvic floor in rectal prolapse. *Ann R Coll Surg Engl* 1962;31:379-404
- Rasmussen OO. Anorectal function. *Dis Colon Rectum* 1994;37:386-403
- Pemberton JH. The clinical value of anorectal motility. *Surg Ann* 1990;22:185-214
- Madoff RD, Williams JG, Caushaj PF. Fecal incontinence. *N Engl J Med* 1992;326:1002-1007
- Douglas JM, Smith LE. Recent concepts in fecal incontinence. *Curr Womens Health Rep* 2001;1:67-71
- Gordon PH. Anorectal anatomy and physiology. *Gastroenterol Clin North Am* 2001;30:1-13
- Shafik A. New concept of the anatomy of the anal sphincter mechanism and the physiology of defecation. II: Anatomy of the levator ani muscle with special reference to the puborectalis. *Invest Urol* 1975;13:175-182
- Duthie HL. Dynamics of the rectum and anus. *Clin Gastroenterol* 1975;4:467-477
- Frenckner B, Euler CV. Influence of pudendal block on the function of the anal sphincters. *Gut* 1975;16:482-489
- Lestar B, Penninckx F, Kerremans R. The composition of anal basal pressure: An in vivo and in vitro study in man. *Int J Colorectal Dis* 1989;4:118-122
- Lamah M, Kumar D. Fecal incontinence. *Dig Dis Sci* 1999 ;44:2488-2499
- Bartolo DC, Roe AM, Locke-Edmunds JC et al. Flap-valve theory of anorectal continence. *Br J Surg* 1986;73:1012-1014
- Miller R, Bartolo DC, Locke-Edmunds JC et al. Prospective study of conservative and operative treatment for faecal incontinence. *Br J Surg* 1988;75:101-105
- Scheuer M, Kuijpers HC, Jacobs PP. Postanal repair restores anatomy rather than function. *Dis Colon Rectum* 1989;32:960-963
- Varma KK, Stephens D. Neuromuscular reflexes of rectal continence. *Austr NZ J Surg* 1972;41:263-272
- Barnes PR, Hawley PR, Preston DM et al. Experience of posterior division of the puborectalis muscle in the management of chronic constipation. *Br J Surg* 1985;72:475-477
- Lunniss PJ, Gladman MA, Hetzer FH et al. Risk factors in acquired faecal incontinence. *J R Soc Med* 2004;97:111-116
- Sainio P, Husa A. Fistula in ano. Clinical features and long term results of surgery in 199 adults. *Acta Chir Scand* 1985;151:169-176
- Farouk R, Bartolo DC. The use of endoluminal ultrasound in the assessment of patients with faecal incontinence. *J R Coll Surg Edinb* 1994;39:312-318
- Milligan ETC, Morgan CN. Surgical anatomy of the anal canal with special reference to anorectal fistulae. *Lancet* 1934;2:1150-1156
- Snooks SJ, Swash M, Mathers SE et al. Effect of vaginal delivery on the pelvic floor: A 5-year follow-up. *Br J Surg* 1990;77:1358-1360
- Parks AG. Anorectal incontinence. *Proc R Soc Med* 1975;68:681-690
- Bharucha AE. Fecal incontinence. *Gastroenterology* 2003;124:1672-1685
- Snooks SJ, Swash M, Henry MM et al. Risk factors in childbirth causing damage to the pelvic floor innervation. *Int J Colorectal Dis* 1986;1:20-24
- Allen RE, Hosker GL, Smith AR et al. Pelvic floor damage and childbirth: a neurophysiological study. *Br J Obstet Gynaecol* 1990;97:770-779
- Neill ME, Parks AG, Swash M. Physiological studies of the anal sphincter musculature in fecal incontinence and rectal prolapse. *Br J Surg* 1981;68:531-536
- Womack NR, Morrison JF, Williams NS. The role of pelvic floor denervation in the aetiology of idiopathic faecal incontinence. *Br J Surg* 1986;73:404-407

38. Beersiek F, Parks AG, Swash M. Pathogenesis of anorectal incontinence: a histometric study of the anal sphincter musculature. *J Neurol Sci* 1979;42:111-127
39. Bidmead J, Cardozo LD. Pelvic floor changes in the older woman. *Br J Urol* 1998;82:18-25
40. Cihak R, Gutmann E, Hanzlikova V. Involution and hormone-induced persistence of the M sphincter (levator) ani in female rats. *J Anat* 1970;106:93-110
41. Haadem K, Ling L, Ferno M et al. Estrogen receptors in the external sphincter. *Am J Obstet Gynecol* 1991;164:609-610
42. Donnelly V, O'Connell PR, O'Herlihy C. The influence of oestrogen replacement on faecal incontinence in postmenopausal women. *Br J Obstet Gynaecol* 1997;104:311-315
43. Sagar PM, Pemberton JH. Anorectal and pelvic floor function. Relevance of continence, incontinence, and constipation. *Gastroenterol Clin North Am* 1996;25:163-182
44. Pemberton JH. Anorectal and pelvic floor disorders: putting physiology into practice. *J Gastroenterol Hepatol* 1990;1:127-143
45. Sangwan YP, Solla JA. Internal anal sphincter: advances and insights. *Dis Colon Rectum* 1998;41:1297-1311
46. Pernikoff BJ, Eisenstat TE, Rubin RJ et al. Reappraisal of partial lateral internal sphincterotomy. *Dis Colon Rectum* 1994;37:1291-1295
47. Barrett JA, Brocklehurst JC, Kiff ES et al. Anal function in geriatric patients with faecal incontinence. *Gut* 1989;30:1244-1251
48. Farouk R, Duthie GS, Pryde A et al. Internal anal sphincter dysfunction in neurogenic faecal incontinence. *Br J Surg* 1993;80:259-261
49. Henry MM. Descending perineum syndrome. In Henry MM, Swash M. (eds) *Coloproctology and the pelvic floor: pathophysiology and management*. London, Butterworths 1985, 299-302
50. Sun WM, Read NW, Miner PB et al. The role of transient internal sphincter relaxation in fecal incontinence? *Int J Colorectal Dis* 1990;5:31-36
51. Epanomeritakis E, Koutsoumbi P, Tsiaoussis I et al. Impairment of anorectal function in diabetes mellitus parallels duration of disease. *Dis Colon Rectum* 1999;42:1394-1400
52. Farouk R, Duthie GS, MacGregor AB et al. Rectoanal inhibition and incontinence in patients with rectal prolapse. *Br J Surg* 1994;81:743-746
53. Lubowski DZ, Nicholls RJ, Burleigh DE et al. Internal anal sphincter in neurogenic fecal incontinence. *Gastroenterology* 1988;95:997-1002
54. Vaizey CJ, Kamm MA, Bartram CI. Primary degeneration of the internal anal sphincter as a cause of passive faecal incontinence. *Lancet* 1997;349:612-615
55. Speakman CT, Hoyle CH, Kamm MA et al. Abnormal internal anal sphincter fibrosis and elasticity in fecal incontinence. *Dis Colon Rectum* 1995;38:407-410
56. Delechenaut P, Leroi AM, Weber J et al. Relationship between clinical symptoms of anal incontinence and the results of anorectal manometry. *Dis Colon Rectum* 1992;35:847-849
57. Rao SS. Pathophysiology of adult fecal incontinence. *Gastroenterology* 2004;126:14-22
58. Goligher JC, Hughes ES. Sensibility of the rectum and colon: its role in the mechanism of anal continence. *Lancet* 1951;1:543-547
59. Scharli AF, Kiesewetter WB. Defecation and continence: some new concepts. *Dis Colon Rectum* 1970;13:81-107
60. Sun WM, Read NW, Miner PB. Relation between rectal sensation and anal function in normal subjects and patients with faecal incontinence. *Gut* 1990;31:1056-1061
61. Hancke E, Schurholz M. Impaired rectal sensation in idiopathic faecal incontinence. *Int J Colorectal Dis* 1987;2:146-148
62. Wald A. Incontinence and anorectal dysfunction in patients with diabetes mellitus. *Eur J Gastroenterol Hepatol* 1995;7:737-739
63. Krogh K, Christensen P, Laurberg S. Colorectal symptoms in patients with neurological diseases. *Acta Neurol Scand* 2001;103:335-343
64. Bannister JJ, Abouzekry L, Read NW. Faecal incontinence in the elderly impacted patients. *Gut* 1986;26:A570
65. Duthie HL, Bennett R. The relation of sensation in the anal canal to the functional anal sphincter: a possible factor in anal continence. *Gut* 1963;4:179-182
66. Maxwell PR, Heriot AG, Davies DC et al. Anorectal sensation and continence. *Scand J Gastroenterol* 1999;34:113-116
67. Holschneider AM, Freeman NV. Anatomy and function of the normal rectum and anus. *Birth Defects Orig Artic Ser* 1988;24:125-154
68. Denis P, Colin R, Galmiche JP et al. Elastic properties of the rectal wall in normal adults and in the patients with ulcerative colitis. *Gastroenterol* 1979;77:45-48
69. Varma JS, Smith AN, Busuttill A. Correlation of clinical and manometric abnormalities of rectal function following chronic radiation injury. *Br J Surg* 1985;72:875-878
70. Goligher JC, Duthie HL, DeDombal FT et al. Abdominoanal pull-through excision for tumors of the mid third of the rectum: a comparison with low anterior resection. *Br J Surg* 1965;52:323-334
71. Lane RH, Parks AG. Function of the anal sphincter following colo-anal anastomosis. *Br J Surg* 1977;64:596-599
72. Emblem R, Stien R, Morkrid L. Anal sphincter function after colectomy, mucosal proctectomy and ileoanal anastomosis. *Scand J Gastroenterol* 1989;24:171-178
73. Beart RW Jr, Dozois RR, Wolf BG et al. Mechanisms of rectal continence. Lessons from the ileoanal procedure. *Ann J Surg* 1985;149:31-34
74. Rasmussen OO, Christiansen J. Physiology and pathophysiology of anal function. *Scand J Gastroenterol* 1996;216:169-174
75. Gordon PH. The anorectum. Anatomic and physiologic considerations in health and disease. *Gastroenterol Clin North Am* 1987;16:1-15
76. Schiller LR, Santa-Ana C, Dans GR et al. Fecal incontinence in chronic diarrhea. Report of a case with improvement after training with rectally infused saline. *Gastroenterol* 1979;77:751-753
77. Jensen LL. Fecal incontinence: evaluation and treatment. *J Wound Ostomy Continence Nurs* 1997;24:277-282
78. O'Kelly TJ, Mortensen NJ. Investigation and management of anorectal incontinence. *Curr Pract Surg* 1992;4:49-55
79. Jorge JM, Wexner SD. Etiology and management of fecal incontinence. *Dis Colon Rectum* 1993;36:77-97
80. Soffer EE, Hull T. Fecal incontinence: a practical approach to evaluation and treatment. *Am J Gastroenterol* 2000;95:1873-1880
81. Kouraklis G, Andromanakos N. Evaluating patients with anorectal incontinence. *Surg Today* 2004;34:304-312

82. Herbst F. Anorectal testing techniques for fecal incontinence. *Chir Gastroenterol* 2001;17:202-207
83. Farouk R, Bartolo DC. Anorectum: clinical measurement of anorectal function. In Kumar D, Wingate D. (eds) *An illustrated guide of gastrointestinal motility*. Edinburgh, Churchill Livingstone 1994, pp.457-463
84. Collier JA. Clinical application of anorectal manometry. *Gastroenterol Clin North Am* 1987;16:17-33
85. Sentovich SM, Wong WD, Blatchford GJ. Accuracy and reliability of transanal ultrasound for anterior anal sphincter injury. *Dis Colon Rectum* 1998;41:1000-1004
86. Pittman JS, Benson JT, Summers JE. Physiologic evaluation of the anorectum: a new ultrasound technique. *Dis Colon Rectum* 1990;33:476-478
87. Tjandra JJ, Milsom JW, Schroeder T et al. Endoluminal ultrasound is preferable to electromyography in mapping anal sphincteric defects. *Dis Colon Rectum* 1993;36:689-692
88. Snooks SJ, Swash M. Nerve stimulation techniques: pudendal nerve terminal motor latency, and spinal stimulation. In Henry MM, Swash M (eds) *Coloproctology and the pelvic floor: pathophysiology and management*. London, Butterworths 1985, pp.112-124
89. Tjandra JJ, Sharma BR, McKirdy HC et al. Anorectal physiological testing in defecatory disorders: A prospective study. *Aust NZ J Surg* 1994;64:322-326
90. Laurberg S, Swash M, Henry MM. Delayed external sphincter repair for obstetric tear. *Br J Surg* 1988;75:786-788
91. Cheong DM, Vaccaro CA, Salanga VD et al. Electrodiagnostic evaluation of fecal incontinence. *Muscle Nerve* 1995;18:612-619
92. Diamant NE, Kamm MA, Wald A et al. AGA Technical review on anorectal testing techniques. *Gastroenterology* 1999;116:735-760
93. MacLeod JH. Management of anal incontinence by biofeedback. *Gastroenterology* 1987;93:291-294
94. Jones HJ, Swift RI, Blake H. A prospective audit of the usefulness of evacuating proctography. *Ann R Coll Surg Engl* 1998;80:40-45
95. Rociu E, Stoker J, Eijkemans MJ et al. Fecal incontinence: endoanal US versus endoanal MR imaging. *Radiology* 1999;212:453-458
96. Roe AM, Bartolo DC, Mortensen NJ. New method for assessment of anal sensation in various anorectal disorders. *Br J Surg* 1986;73:310-312
97. Andromanakos N, Deen IK, Grant AE et al. Anorectal physiology in the assessment and management of patients with faecal incontinence. *Hell J Gastroenterol* 1996;9:151-154
98. Miller R, Bartolo DC, Cervero F et al. Anorectal temperature sensation: a comparison of normal and incontinent patients. *Br J Surg* 1987;74:511-515