

Endosonographic Surveillance of Small Gastrointestinal Tumors Originating from Muscularis Propria

Ka-Ho Lok², Lawrence Lai², Hak-Lim Yiu¹, Ming-Leung Szeto², Siu-Kee Leung¹

1) Department of Surgery, Tuen Mun Hospital, Hong Kong; 2) Department of Medicine and Geriatrics, Tuen Mun Hospital, Hong Kong

Abstract

Introduction. Submucosal tumors (SMT) are not uncommonly found during upper endoscopy. Management for small SMT originating from muscularis propria (MP) is controversial. Data regarding regular endoscopic ultrasound (EUS) surveillance is scarce. We report our experience in using EUS to monitor these tumors. **Methods.** Patients with SMT originated from MP as confirmed by EUS were recruited. The maximal diameter, echopattern, presence of cystic spaces and regularity of extra-luminal margin were documented. Patients with large tumors (maximal diameter > 3 cm), heterogeneous echopattern, presence of cystic spaces or irregular extra-luminal margin were offered surgery in view of malignant risk. Patients with small tumor and benign EUS features were offered regular EUS surveillance or surgery if they wished. The progress of those patients who underwent EUS surveillance were studied. **Results.** From January 2002 to December 2007, there were 93 patients with SMT originating from MP. Forty-nine patients had a small tumor and benign EUS features. Only two of these patients chose surgery. The histopathological results were low risk gastrointestinal stromal tumor (GIST) in both patients. Twenty-three patients elected to undergo regular EUS surveillance for a mean period of 17.3 months (range 6 – 42 months). Three patients (13.0%) showed interval increase in tumor size. There was no change in other EUS features. Surgery was performed in these 3 patients. Histological examination revealed schwannoma in 2 patients and low risk GIST in 1 patient. **Conclusion.** It remains unclear whether EUS surveillance for small tumors originating from MP in the upper gastrointestinal tract is useful.

Keywords

Endosonographic – endoscopic ultrasound – surveillance – muscularis propria – GIST.

Introduction

Submucosal tumor (SMT) refers to a bulge underneath the mucosa of the gastrointestinal tract whose etiology cannot be determined by endoscopy with superficial mucosal biopsies [1]. Evaluation of SMT is one of the classical indications of endoscopic ultrasound (EUS). It is the most important tool to assess its layer of origin, differential diagnosis, classification and follow up of these lesions [1-6]. Due to the popularity of endoscopic examination, SMTs are not uncommonly found. A significant proportion of these originate from the muscularis propria (MP) layer. Management usually requires surgical removal as endoscopic resection carries a high risk of perforation. However, management for small gastrointestinal MP tumors is not well defined. These tumors are usually benign and their progression may be slow. It is probably too aggressive and not cost-effective to recommend surgery for all patients with small gastrointestinal MP tumors. On the other hand, many experts would adopt a strategy to monitor these tumors regularly by EUS. However, data regarding regular EUS surveillance for small gastrointestinal MP tumors are scarce. The usefulness, interval and duration of this endosonographic surveillance remain unanswered. We performed a retrospective study to describe our experience of using EUS to monitor the progression of these small gastrointestinal MP tumors.

Patients and Methods

All patients who underwent EUS examinations in Tuen Mun Hospital for the evaluation of upper gastrointestinal SMTs from January 2002 to December 2007 were identified through the Clinical Management System (CMS), a computerized medical record system utilized by Hong Kong Hospital Authority. Our hospital is a public regional hospital with 1,405 acute beds, serving a population of 1,095,400 in the year 2006. Those patients with SMT originating from the

Received: 26.10.2008 Accepted: 24.12.2008

J Gastrointest Liver Dis

June 2009 Vol.18 No 2, 177-180

Address for correspondence:

Dr Ka-Ho Lok
Tuen Mun Hospital
Tsing Chung Koon Road, Tuen Mun
New Territories, Hong Kong
E-mail: lokkaho@netvigator.com

MP as confirmed by EUS were recruited for this analysis. Their medical notes were examined and the following information was retrieved for analysis: (1) sex and age of the patients, (2) location of the tumors, (3) maximal diameter of the tumor, (4) EUS characteristics such as regularity of extra-luminal border, echopattern (homogeneous or heterogeneous), presence of cystic spaces or echogenic foci, (5) presumptive EUS diagnosis, (6) number of EUS examinations, (7) duration of EUS follow up, (8) operation records and (9) histopathological results if available.

Endosonographic examination was performed using a mechanical radial echoendoscope Olympus GF-UM20 (from 2002 to 2004) or Olympus GF-UM2000 (from 2005 to 2007). The scanning frequency ranged from 5 MHz to 20 MHz. All examinations were performed by 1 of 4 experienced endosonographers who had performed more than 150 diagnostic EUS examinations. For assessment of SMT, it is our routine practice to record the tumor location, layer of origin, maximal diameter, regularity of extra-luminal border, echopattern and presence of cystic spaces or echogenic foci in order to provide a presumptive diagnosis and predict their malignant risk. Endosonographic features suggestive of a risk of malignancy including large size, irregular extra-luminal border, heterogeneous echopattern, presence of cystic spaces and echogenic foci have been well described in previous studies [7-8]. Endosonographic guided fine-needle aspiration or tru-cut biopsy were not available in our centre during this study period.

Patients with large tumor (maximal diameter > 3cm) or other high risk EUS features were advised to undergo surgical removal in view of the risk of malignancy. Patients with small tumor and absence of high risk EUS features were advised to have regular EUS surveillance (repeated at 6 months and then annually) to monitor any progression or surgery if they strongly wished. For those patients who had their tumor removed surgically, the histopathological results were analyzed to determine its nature and presence of malignancy. For gastrointestinal stromal tumor (GIST), the malignant risk was graded as very low, low, intermediate or high according to international consensus criteria [9]. The progress in those patients who underwent regular EUS surveillance was studied. Any changes in tumor size and EUS characteristics were recorded. In view of possible variations in the scanning during measurement of maximal

tumor diameter in follow-up examination, an increase of at least 5mm was considered as a significant increase in tumor size. Presence of other EUS features was subjected to the endosonographer's own judgment. Surveillance was performed at 6 months after the index EUS and then annually. Patients with a significant increase in tumor size or development of high risk EUS characteristics were advised to undergo surgery.

Results

From January 2002 to December 2007, there were a total of 93 patients who evidenced SMT originating from muscularis propria. The mean age was 62.2 years (range 23 – 92 years) and 51 patients were male (M: F = 1.2: 1). The tumors were most commonly located in the gastric body (n = 53), followed by gastric fundus (n = 20), esophagus (n = 11), gastric antrum (n = 6) and duodenum (n = 3). The EUS characteristics of MP tumors in different locations at the index endosonographic examinations are shown in Table I. There were 49 patients who had a small tumor without high risk EUS features. Two of these patients chose to undergo surgical treatment and the histopathological result was low grade GIST. Twenty-three of them agreed for regular EUS surveillance to monitor the tumor progression.

Twenty-three patients had a median size of tumor, 12.9±6.9mm at index EUS examination. Endosonographic surveillance was performed over a mean period of 17.3±10.2 months. Only 3 patients (13.0%) showed interval increase in tumor size. There was no change in other EUS features in these patients. Surgical excisions were performed in these 3 patients. Histopathological examination revealed schwannoma in 2 patients and low risk GIST in 1 patient. Detailed information regarding these lesions is shown in Table II.

Discussion

Due to the popularity of endoscopic examination, gastrointestinal submucosal mass is not uncommon. The exact incidence of SMTs is difficult to assess because most of them are asymptomatic. It is estimated to be around 0.3% [10]. Evaluation of SMT is best performed by EUS to determine its size, layer of origin, presumptive diagnosis, malignant sonographic features and guide the appropriate

Table I. Features of muscularis propria tumors in all 93 patients during initial endosonographic examinations

Localization	No. of patients	Sex (M: F)	Age (years, mean +/- SD)	Max. diameter (mm, mean +/- SD)	Irregular border (no. of patients)	Heterogeneous echopattern (no. of patients)	Cystic spaces (no. of patients)
Oesophagus	11	5: 6	61.2 +/- 13.2	20.1 +/- 12.5	1	1	2
Gastric fundus	20	13: 7	65.9 +/- 14.8	17.0 +/- 12.2	2	2	0
Gastric body	53	29: 24	61.9 +/- 13.6	26.8 +/- 17.8	9	17	7
Gastric antrum	6	3: 3	54.0 +/- 28.2	23.2 +/- 13.6	1	2	1
Duodenum	3	1: 2	64.0 +/- 4.0	42.1 +/- 35.4	1	1	0

Table II. Patients with interval tumor enlargement during EUS follow up

Patient	Location of SMT	Duration of EUS follow up (months)	Change in size (mm)	Malignant features	Histopathological diagnosis
53	Gastric body	24	16 to 23.5	no	Schwannoma
54	Gastric body	20	16 to 21	no	Schwannoma
59	Gastric body	21	20 to 26	no	Low risk GIST

management [1-6]. Removal of small SMT originating from submucosal layer (3rd sonographic layer) without involvement of MP (4th sonographic layer) can be safely accomplished by endoscopic resection [11]. However, removal of tumor originating from proper muscular layer requires surgery as endoscopic resection carries a high risk of perforation. The natural history of small MP tumors is not well defined. The majority of these small tumors are benign and their progression may be slow. Some authors have suggested that all GISTs should be treated by surgery because even small tumors can occasionally metastasize, sometimes with a delay of many years [12-14]. However, this risk is small and surgery for all is probably too aggressive and not cost effective. Regular EUS surveillance to monitor interval changes in size and sonographic features is another commonly employed strategy (Fig. 1). Data regarding its usefulness is lacking and there are currently no guidelines on the surveillance strategies.

Our experience showed that only a few small MP tumors (3 out of 23, 13%) progress during long-term follow-up. All these patients with progressive MP tumors can undergo early surgical treatment but one tumor was a low grade GIST and the other two were schwannomas with no malignant features. Therefore, the usefulness of regular EUS surveillance remained un-established. In an earlier study, Melzer et al followed 25 patients with SMT by EUS over a mean period of 19 months [15]. One patient developed interval tumor enlargement from a diameter of 30mm to 38mm. This patient was found to have GIST with a high malignancy potential. However, this study recruited patients with gastrointestinal wall tumors originating from both submucosa and MP. Our study was the first one that directly addressed these small tumors originating from MP in which the management is controversial.

Our study has a few limitations, including retrospective design with a small number of patients monitored over a relatively short period. This reflects the fact that gastrointestinal MP tumors such as GIST, schwannoma and leiomyoma remain rare tumors and a large scale study is difficult to conduct. Being the most common MP tumor encountered, GIST comprises only about 1% of all gastrointestinal neoplasms [1]. Secondly, although supported by previous data in the literature [8], the cut-off diameter of 3 cm is arbitrarily chosen and EUS guided FNA is not performed in our patients so that the exact nature of the tumor cannot be determined. The precise histopathological diagnosis could be difficult to achieve with FNA because most GISTs are difficult to penetrate, with fibrosis that

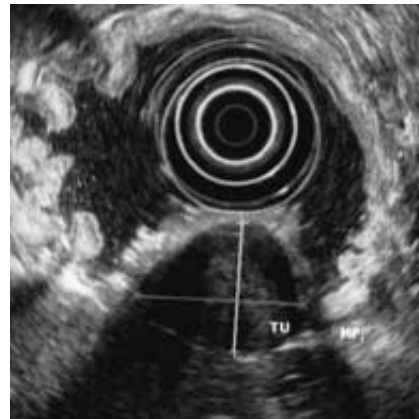


Fig 1. Small hypoechoic tumor originated from muscularis propria layer of stomach suggestive of small gastric GIST.

frequently prevents achievement of sufficient material by aspiration [16]. Even though the diagnosis can be made with immunohistochemistry, malignant potential based on the mitotic count cannot be properly evaluated with a cytology specimen.

Furthermore, there are size limitations of EUS-guided techniques. According to a study by Akahoshi et al, the yield of sufficient tissue acquisition seems to be dependent on the tumour diameter, being 71%, 86% and 100% for a tumor less than 2 cm, 2 cm to 4 cm, and more than 4 cm in diameter, respectively [14]. Trucut biopsy needle to obtain a core of tissue for histological evaluation may solve the problem but a well conducted study specifically for GIST is lacking. Also, EUS-guided trucut biopsy is difficult to perform in tumors less than 2cm in size. Thirdly, the appearance of benign and malignant lesions overlaps and there may be interobserver variation in assessing different EUS features, leading to an overall accuracy of only 80% [7]. Fourthly, a tumor in different location may exhibit different behavior. For instance, small MP tumors in the esophagus are usually benign leiomyomas, whereas GISTs in the small intestine can display unpredictable malignant behavior and carry a worse prognosis than gastric tumors [17]. Finally, only 23 of the 49 patients with small MP tumors (46.9%) agreed to be subjected to regular EUS follow-up. The poor compliance of the patients to regular EUS surveillance is another important limitation to this approach. This is probably related to the invasive nature and discomfort of endoscopic examination. Taking into account the small percentage of GISTs that need surgery after regular EUS follow-up, this shows a possible

lack of cost-effectiveness for this approach. Polkowski et al have reported the use of transabdominal ultrasound as a non-invasive and inexpensive method for surveillance in patients with SMT [18]. However, only 69% of patients with EUS diagnosed gastric SMTs can be visualized using transabdominal ultrasound of water-filled stomach.

In the future, prospective controlled trials should be performed to test the capability of tru-cut biopsy of small MP tumors in determining malignancy. Molecular analysis of c-kit or PDGFR- α mutations in EUS-FNA specimens may be useful to provide tissue diagnosis and assess the malignant risk [19]. Studies using more objective criteria such as color doppler and elastography in predicting malignant potential may provide more clues to appropriate management [20-21]. Emerging endoscopic techniques such as band ligation [22] or transluminal closure after endoscopic resection [23-24] may be the ultimate minimally invasive treatment options for safe en-bloc tumor removal.

Conclusion

Based on our experience in a single center, it remains unclear that regular EUS surveillance for small tumours origination from muscularis propria in upper gastrointestinal tract is indeed useful or cost-effective. However, our study offers important data regarding the natural history of small GISTs.

Conflicts of interest

None to declare.

References

- Chak A. EUS in submucosal tumors. *Gastrointest Endosc* 2002; 56 (4 Suppl): S43-S48.
- Gordon SJ, Rifkin MD, Goldberg BB. Endosonographic evaluation of mural abnormalities of the upper gastrointestinal tract. *Gastrointest Endosc* 1986; 32: 193-198.
- Tio TL, Tytgat GNJ, den Hartog Jager FC. Endoscopic ultrasonography for the evaluation of smooth muscle tumors in the upper gastrointestinal tract: an experience with 42 cases. *Gastrointest Endosc* 1990; 36: 342-350.
- Boyce GA, Sivak MV Jr, Rosch T, et al. Evaluation of submucosal upper gastrointestinal tract lesions by endoscopic ultrasound. *Gastrointest Endosc* 1991; 37: 449-454.
- Rosch T, Lorenz R, Dancygier H, von Wickert A, Classen M. Endosonographic diagnosis of submucosal upper gastrointestinal tract tumors. *Scand J Gastroenterol* 1992; 27: 1-8.
- Lambert R, Caletti G, Cho E, et al. International Workshop on the clinical impact of endoscopic ultrasound in gastroenterology. *Endoscopy* 2000; 32: 549-584.
- Chak A, Canto MI, Rosch T, et al. Endosonographic differentiation of benign and malignant stromal cell tumors. *Gastrointest Endosc* 1997; 45: 468-473.
- Palazzo L, Landi B, Cellier C, Cuillierier E, Roseau G, Barbier JP. Endosonographic features predictive of benign and malignant gastrointestinal stromal cell tumors. *Gut* 2000; 48: 88-92.
- Fletcher CD, Berman JJ, Corless C, et al. Diagnosis of gastrointestinal stromal tumours: A consensus approach. *Hum Pathol* 2002;33:459-465.
- Hedenbro JL, Ekelund M, Wetterberg P. Endoscopic diagnosis of submucosal gastric lesions. The result after routine endoscopy. *Surg Endosc* 1991; 5: 20-23.
- Shim CS, Jung IS. Endoscopic removal of submucosal tumors: preprocedure diagnosis, technical options, and results. *Endoscopy* 2005; 37: 646-654.
- Bandoh T, Isoyama T, Toyoshima H. Submucosal tumors of the stomach: a study of 100 operative cases. *Surgery* 1993; 113: 498-506.
- Joensuu H, Fletcher C, Dimitrijevic S, Silberman S, Roberts P, Demetri G. Management of malignant gastrointestinal stromal tumours. *Lancet Oncol* 2002; 3: 655-664.
- Akahoshi K, Sumida Y, Matsui N, et al. Preoperative diagnosis of gastrointestinal stromal tumor by endoscopic ultrasound-guided fine needle aspiration. *World J Gastroenterol* 2007; 13: 2077-2082.
- Melzer E, Fidler H. The natural course of upper gastrointestinal submucosal tumors: an endoscopic ultrasound survey. *Isr Med Assoc J* 2000; 2(6): 430-432.
- Wiech T, Walch A, Werner M. Histopathological classification of nonneoplastic and neoplastic gastrointestinal submucosal lesions. *Endoscopy* 2005; 37: 630-634.
- Davila RE, Faigel DO. GI stromal tumors. *Gastrointest Endosc* 2003; 58: 80-88.
- Polkowski M, Palucki J, Butruk E. Transabdominal ultrasound for visualizing gastric submucosal tumors diagnosed by endosonography: can surveillance be simplified? *Endoscopy* 2002; 34: 979-983.
- Gomes AL, Bardales RH, Milanezi F, Reis RM, Schmitt F. Molecular analysis of c-Kit and PDGFRA in GISTs diagnosed by EUS. *Am J Clin Pathol* 2007; 127: 89-96.
- Saftoiu A, Vilmann P, Hassan H, Krag Jacobsen G. Utility of colour Doppler endoscopic ultrasound evaluation and guided therapy of submucosal tumors of the upper gastrointestinal tract. *Ultraschall Med* 2005; 26: 487-495.
- Gheorghe L, Gheorghe C, Cotruta B, Carabela A. CT aspects of gastrointestinal stromal tumors: adding EUS and EUS elastography to the diagnostic tools. *J Gastrointest Liver Dis.* 2007; 16: 346-347.
- Sun S, Ge N, Wang C, Wang M, Lü Q. Endoscopic band ligation of small gastric stromal tumors and follow-up by endoscopic ultrasonography. *Surg Endosc* 2007; 21: 574-578.
- Ryou M, Fong DG, Pai RD, Rattner DW, Thompson CC. Transluminal closure for NOTES: an ex vivo study comparing leak pressures of various gastrotomy and colotomy closure modalities. *Endoscopy* 2008; 40: 432-436.
- Chiu PW, Lau JY, Ng EK, et al. Closure of a gastrotomy after transgastric tubal ligation by using the Eagle Claw VII: a survival experiment in a porcine model. *Gastrointest Endosc.* 2008; 68: 554-559.