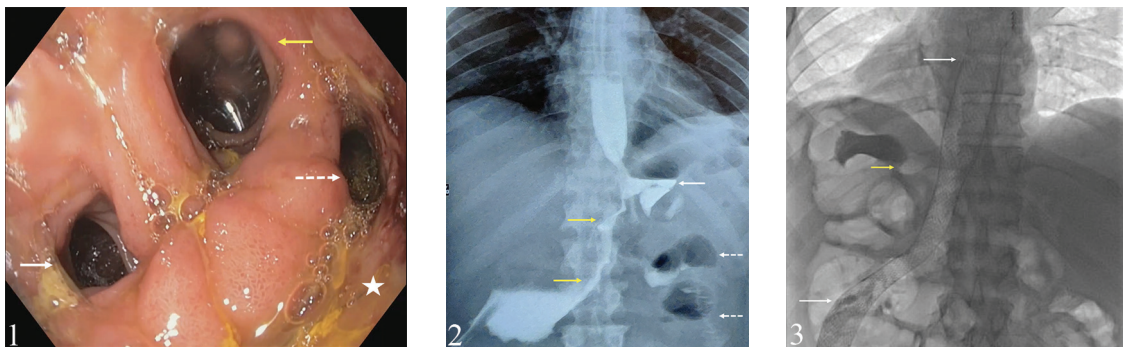


A Novel Endoscopic Procedure for the Management of an Esophago-jejunal Anastomotic Leak post-Whipple Procedure

Naveen Kumar¹, Jahnvi Dhar², Vikas Gupta³, Jayanta Samanta⁴

1) Department of Gastroenterology, Sri Harihar Hospital and Research Centre, Mandi, Himachal Pradesh; 2) Department of Gastroenterology and Hepatology, Punjab Institute of Liver and Biliary Sciences, Mohali, Punjab; 3) Department of Surgical Gastroenterology, Post Graduate Institute of Medical Education and Research, Chandigarh; 4) Department of Gastroenterology, Post Graduate Institute of Medical Education and Research, Chandigarh, India



A 40-year-old gentleman, post-Whipple's with total gastrectomy for periampullary carcinoma with contiguous gastric involvement, developed fever post-operative day 10. He underwent abdominal contrast-enhanced computed tomography which revealed esophago-jejunal anastomotic leak with multiple intraabdominal collections. After percutaneous drain placement, he underwent a gastroscopy which revealed an ulcerated esophago-jejunal anastomotic site (Fig. 1, solid white asterisk) with leak (Fig 1, white dotted arrow), and patent afferent and efferent jejunal loops (Fig 1, efferent jejunal loop opening: yellow solid arrow, afferent jejunal loop opening: white solid arrow). The findings were confirmed on water soluble contrast study [Fig. 2, the blind loop (afferent jejunal limb; white solid arrow); filling of efferent loop (dotted white arrow) and site of active leak (yellow solid arrow) at the site of anastomosis]. Considering various options on multidisciplinary team discussion, placement of MEGATM stent was planned. Under fluoroscopic and endoscopic guidance, a MEGATM stent (Niti-S fully covered self-expanding metal stent, Taewoong medical, South Korea) of size 24 mm x 23 cm was placed over a steel guidewire in the efferent limb covering the site of the anastomosis and leak (Fig. 3). Post-procedure, purulent output in the percutaneous drains subsided and were subsequently removed. Contrast study and abdominal CECT, post-stenting, showed no leak and contrast was seen flowing into the distal jejunum. Repeat endoscopy after 1-week showed an optimally placed stent covering both the anastomotic site till the distal jejunum covering the leak site. The patient was discharged on post-operative day 39 and

had no subsequent reports of any leak. However, he succumbed to his basic disease 6-months post procedure.

Endoscopic management is the current first-line approach for post-surgical leaks, perforation or fistulae [1]. MEGATM esophageal stents are fully covered stents with a large diameter and long length and can effectively bridge large anastomotic defects [2]. They have been commonly used for the treatment of post-bariatric leaks, with a clinical success of up to 80% with 18% migration risk [3]. The use of MEGA stent in our index case is unique as its use has never been described in a post-Whipple's leak and can be effectively used as a minimally invasive option.

Corresponding author: Jayanta Samanta, dj_samanta@yahoo.co.in; samanta.jayanta@pgimer.edu.in

Conflicts of interest: None to declare.

REFERENCES

1. Tringali A, Bove V, Perri V, et al. Endoscopic treatment of post-laparoscopic sleeve gastrectomy leaks using a specifically designed metal stent. *Endoscopy*. 2017;49:64-8. doi:[10.1055/s-0042-119080](https://doi.org/10.1055/s-0042-119080)
2. Basha J, Appasani S, Sinha SK, et al. Mega stents: a new option for management of leaks following laparoscopic sleeve gastrectomy. *Endoscopy*. 2014;46:E49-E50. doi:[10.1055/s-0034-1365397](https://doi.org/10.1055/s-0034-1365397)
3. Shehab H, Abdallah E, Gawdat K, Elattar I. Large bariatric-specific stents and over-the-scope clips in the management of post-bariatric surgery leaks. *Obes Surg*. 2018;28:15-24. doi:[10.1007/s11695-017-2799-9](https://doi.org/10.1007/s11695-017-2799-9)