

Primary Hepatic Amyloidosis Presenting as Nodular Masses on the Background of Diffuse Infiltration and Extreme Liver Stiffness on MR Elastography

Sivasubramanian Srinivasan¹, Yi Qi Tan¹, Hui Seong Teh¹, Piao Jarrod Lee², Ree Nee Khoo¹

1) Department of Diagnostic Radiology,
2) Department of Gastroenterology,
Khoo Teck Puat Hospital,
Singapore 768828
Republic of Singapore

Address for correspondence:
Sivasubramanian Srinivasan
Department of Diagnostic Radiology,
Khoo Teck Puat Hospital
90 Yishun Central,
Singapore 768828
Republic of Singapore.
sivasu2@gmail.com

Received: 24.09.2014
Accepted: 10.10.2014

ABSTRACT

Amyloidosis is characterized by the deposition of extracellular protein material, amyloid, in various organs. The clinical and imaging features of the disease are often nonspecific and a tissue biopsy is often required. We present the case of a 64-year-old man with biopsy proven amyloidosis of the liver. The patient presented with non-specific clinical symptoms. Routine imaging showed hepatomegaly with heterogeneous enhancement, and several large nodular space occupying lesions, mimicking neoplasm. MR elastography revealed an extremely stiff liver. Amyloidosis presenting as multiple nodular masses on the background of diffuse infiltrative pattern or demonstration of extreme stiffness in hepatic amyloidosis on MR elastography have not been described previously.

Key words: amyloidosis – liver – computed tomography – magnetic resonance (MR) imaging – MR elastography.

INTRODUCTION

Primary amyloidosis is a rare systemic disorder. Involvement of viscera such as heart and kidneys may result in progressive loss of function which may lead to death. Liver and spleen are also commonly involved [1] but often remain clinically silent except for enlargement. Abnormal liver function with resultant portal hypertension may occur, which is considered as a bad prognostic sign; rarely can it be localized to one or few organs [2]. Imaging findings are usually nonspecific. We report the case of a patient with localized primary hepatic amyloidosis presenting as masses on routine imaging and extreme stiffness on strain imaging with magnetic resonance (MR) elastography.

CASE REPORT

A 64-year-old man presented with non-specific clinical symptoms (left leg pruritis and edema). Routine clinical examination revealed hepatomegaly with hard irregular edges. Serum alkaline phosphatase and gamma glutamyl transpeptidase levels were elevated (428 IU/L and 545 IU/L, respectively). Serum bilirubin and transaminases were within normal limits. Tests were negative for hepatitis B and C. Serum alpha-feto protein was not elevated.

The patient's medical history revealed that he had been evaluated for hepatomegaly three years ago but defaulted treatment. At that time, computed tomography (CT) scan revealed enlarged liver with mosaic attenuation and no mass lesions. Present CT and magnetic resonance (MR) imaging showed hepatomegaly with heterogeneous enhancement, and several large nodular space occupying lesions (Figs. 1, 2), which were slightly more hyperdense than the rest of liver parenchyma and showed delayed enhancement, mimicking neoplasia. There was a mass effect compressing on the hepatic veins and some of these nodules were partially exophytic. MR elastography at 3 Tesla (3T) revealed extremely stiff liver (6.9 kPa to 14.4 kPa, normal < 2.1 kPa) (Fig. 3). The spleen was not enlarged. Ultrasonography-guided biopsy of the liver (from

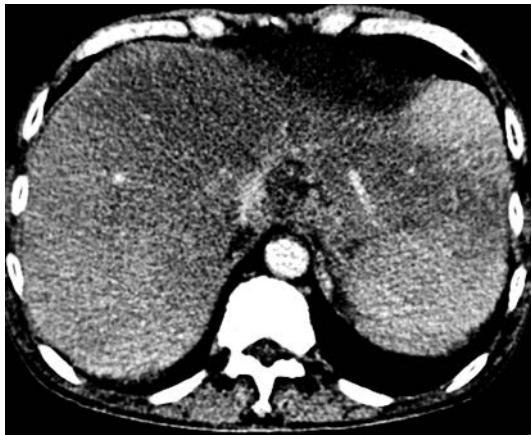

Fig. 1. Axial contrast-enhanced CT: hypodense liver with heterogeneous enhancement.

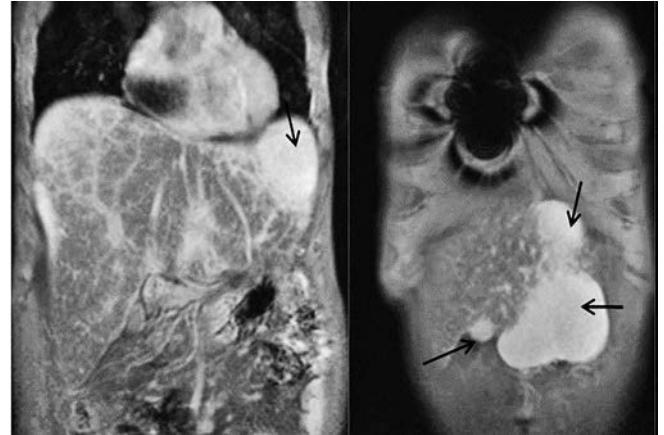


Fig. 3. Post contrast MRI of the liver (delayed phase): heterogeneous enhancement of the parenchyma with nodular lesions showing increased enhancement as compared to the rest of the liver (black arrows).

multiple sites) was performed. Histopathological evaluation of the specimen showed extracellular eosinophilic material with positive staining with Congo red and characteristic “apple-green” birefringence on polarized microscopy. Immunoperoxidase staining with both kappa and lambda chains was positive. These features were consistent with primary amyloidosis.

DISCUSSION

Amyloidosis is a condition characterized by deposition of abnormal fibrillary proteins called amyloid proteins.

The structure of these proteins is different from that of the regular proteins which comprise alpha-helix strands that are easily soluble. The amyloid proteins comprise numerous beta strands which aggregate to form B sheet protofilament. Due to repetitive structure, they stain positive with Congo red stain, and when viewed under microscope, they show an apple-green birefringence [3]. These abnormal proteins are often resistant to the proteolytic process [1]. Progressive deposition may replace the normal tissues in various organs and can cause impairment of function. Amyloidosis is usually a systemic disease, but can be a focal disease in 10-20% of the patients. The two main forms of amyloidosis include primary

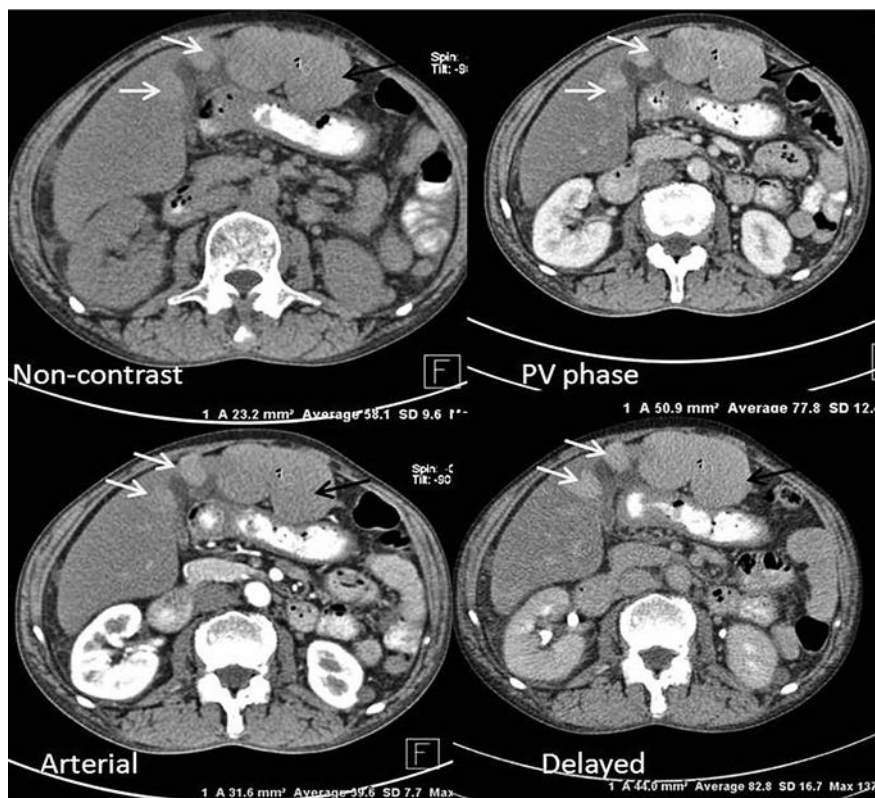


Fig. 2. Dedicated multi-phasic axial CT sections of the liver: nodular areas (white arrows) with increasingly dense enhancement in portal venous and delayed phases. Few of the lesions (black arrows) are exophytic, especially in the left lobe. The rest of the abdomen - unremarkable.

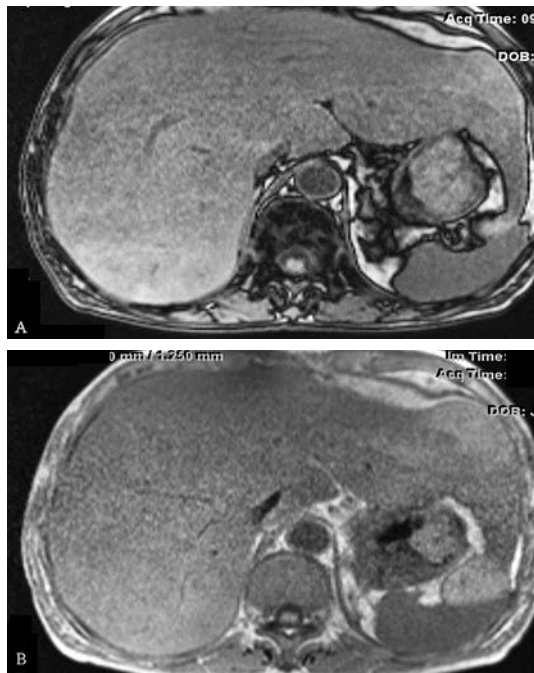


Fig. 4. Out-phase (A) and In-phase (B) T1-w sequence. No evident fatty infiltration or iron deposition.

amyloidosis which is also known as amyloid light-chain (AL) amyloidosis and secondary amyloidosis, which is known as amyloid A (AA) amyloidosis [1, 3]. Primary amyloidosis can be associated with B-cell dyscrasias, such as multiple myeloma. Secondary amyloidosis can co-exist with chronic disorders such as tuberculosis, ankylosing spondylitis, rheumatoid arthritis or some long standing malignancies, especially renal cell carcinoma. Apart from the two main types, few minor forms of amyloidosis include B2-microglobulin type (AB2-M) and familial types such as transthyretic (ATTR) types.

Clinical features are often nonspecific. Amyloidosis may be suspected in patients with chronic infectious or inflammatory conditions resulting in new onset nephrotic syndrome or proteinuria. However, it is very difficult to diagnose primary amyloidosis clinically. Primary (AL) amyloidosis can present with restrictive cardiomyopathy or peripheral neuropathy. Other features of AL amyloidosis include generalized fatigue, loss of weight, skin lesions, pseudohypertrophy of muscles, xerostomia, hoarseness of voice etc. Symptoms may occur

according to the organ involved. In the oral cavity, it can cause macroglossia or xerostomia. The commonest system to be involved in the abdomen is the gastrointestinal system and the commonest part involved is the colon.

Although focal involvement of the liver is extremely rare, amyloidosis is known to involve the liver [2, 4]. Usually the clinical signs are minimal or absent and the liver function tests are not affected. However, portal hypertension and liver failure have been reported and are usually associated with poor prognosis [5]. Imaging findings are often nonspecific and it is difficult to diagnose amyloidosis based on ultrasonography (US), computed tomography (CT) or MR imaging; biopsy is often necessary for the diagnosis. US findings are nonspecific and only heterogeneous echopattern of the liver may be detected. Diffuse infiltration of amyloid may be seen as heterogeneous parenchymal enhancement in the venous phase of the contrast-enhanced CT scan images. Delayed enhancement may be present, which could be probably due to delayed uptake of contrast by the amyloid material [2]. Rarely, it can present with rupture and marked calcifications [2]. MR imaging may show decreased signal in T2-weighted images or increased signal in T1-weighted images [1]. However, this finding is non-specific and it was not observed in our patient. Liver amyloidosis presenting as focal masses is extremely rare and only one such case has been reported until now [4]. In this case, hypodense masses were demonstrated by CT with areas of calcification. In our patient, masses were present and the liver also showed heterogeneous enhancement; on biopsy, amyloid deposition was detected in the masses as well as in the liver parenchyma. No calcified foci were seen in the liver.

Increased liver stiffness in hepatic amyloidosis has been described at sonoelastography [6, 7]. However, MR elastographic findings of liver amyloidosis have not been previously described. Because of the diffuse infiltration of the liver, the liver becomes extremely stiff, as in our patient, with very high strain values. Apart from the unusual presentation of amyloidosis as focal masses on the background of diffuse infiltration, this case also highlights the utility of strain imaging with MR elastography in such cases. MR elastography provides a better assessment of liver stiffness, being deprived of the disadvantages of US elastography, such as shallow wave propagation, subjective variation and poor utility in obese patients [8, 9].

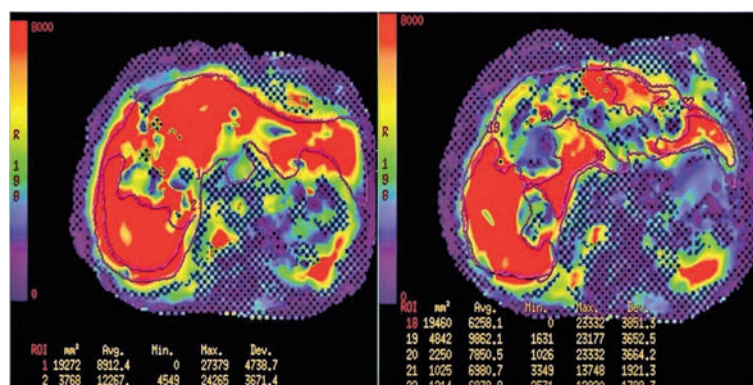


Fig. 5. MR Elastography (3Tesla): extreme stiffness of the liver (6.9 kPa to 14.4 kPa)

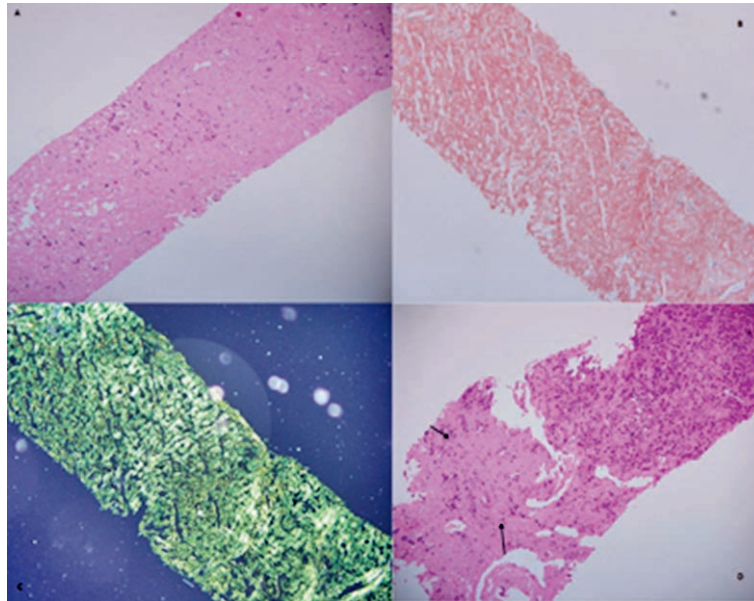


Fig. 6. Biopsy specimen from the liver tissue. (a) Photomicrograph (H&E stain) showing collagen type extracellular material. (b) Congo-red stain revealing strong affinity of the material. (c) Characteristic “apple-green” birefringence on polarized light microscopy, consistent with amyloidosis. (d) Core tissue showing amyloid (black arrows) adjacent to residual hepatic parenchyma (white arrow): the transitional zone shows amyloid infiltrating between plates of hepatocytes, replacing the sinusoids.

CONCLUSION

Although biopsy is necessary for the final diagnosis, strain imaging is very helpful in providing the differential diagnosis. Liver amyloidosis can be considered as one of the causes of unexplained stiffness in a non-cirrhotic liver. Radiologists should be aware of the rare appearance of amyloidosis, mimicking a mass, and of the value of strain imaging, especially MR elastography, in diffuse infiltrative conditions such as amyloidosis.

Conflicts of interest: None.

REFERENCES

1. Monzawa S, Tsukamoto T, Omata K, Hosoda K, Araki T, Sugimura K. A case with primary amyloidosis of the liver and spleen: radiologic findings. *Eur J Radiol* 2002;41:237–241.
2. Shin YM. Hepatic amyloidosis. *Korean J Hepatol* 2011;17:80–83.
3. Pettersson T, Kontinen YT. Amyloidosis – recent developments. *Semin Arthritis Rheum* 2010;39:356–368.
4. Son RC, Chang JC, Choi JH. Primary hepatic amyloidosis: report of an unusual case presenting as a mass. *Korean J Radiol* 2011;12:382–385.
5. Georgiades CS, Neyman EG, Barish MA, Fishman EK. Amyloidosis: review and CT manifestations. *Radiographics* 2004;24:405–416.
6. Janssens F, Spahr L, Rubbia-Brandt L, Giostra E, Bihl F. Hepatic amyloidosis increases liver stiffness measured by transient elastography. *Acta Gastroenterol Belg* 2010;73:52–54.
7. Lanzi A, Gianstefani A, Mirarchi MG, Pini P, Conti F, Bolondi L. Liver AL amyloidosis as a possible cause of high liver stiffness values. *Eur J Gastroenterol Hepatol* 2010;22:895–897.
8. Cohen EB, Afdhal NH. Ultrasound-based hepatic elastography: origins, limitations, and applications. *J Clin Gastroenterol* 2010;44:637–645.
9. Mariappan YK, Glaser KJ, Ehman RL. Magnetic resonance elastography: a review. *Clin Anat* 2010;23:497–511.