

# Primary MALT Lymphoma of the Gallbladder. Case Report

Matthew Koshy, Frank Zhao, Michael C. Garofalo

University of Maryland School of Medicine, Baltimore, MD, USA

## Abstract

Primary lymphomas of mucosa associated lymphoid tissue (MALT) are exceedingly rare. We report the case of a 51 year old female diagnosed with primary MALT lymphoma of the gallbladder after cholecystectomy. Further staging workup was negative for metastatic disease. When the disease is localized to the gallbladder, primary MALT lymphomas of the gallbladder carry an excellent prognosis, and surgical resection is curative in the majority of cases.

## Key words

Gallbladder - MALT lymphoma – NH lymphoma – prognosis

## Introduction

Non-Hodgkin lymphoma (NHL) involving the gallbladder is rare. The majority of cases described involve secondary infiltration of the gallbladder consequent to widespread disease [1]. Primary NHL of the gallbladder is limited to only 16 reported cases in the English medical literature [2].

Considering all non-Hodgkin lymphomas, extranodal lymphomas of mucosa associated lymphoid tissue (MALT) are the third most common [3]. These low-grade malignancies were initially described in the gastrointestinal (GI) tract, however they have since been reported in a number of mucosal sites including the lung, thymus, breast and others [4-6]. Primary MALT lymphomas of the gallbladder are exceedingly rare with only six cases having been previously reported in the medical literature [1]. Here we report the

seventh case of primary MALT lymphoma of the gallbladder and a relevant literature review.

## Clinical case summary

A 51 year old female initially presented with a several month history of intermittent post-prandial pain localized to the right upper quadrant. At that time, she underwent a HIDA scan which was abnormal and was scheduled for a laparoscopic cholecystectomy.

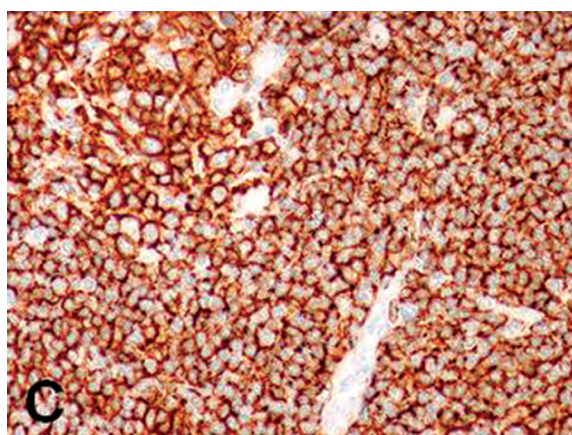
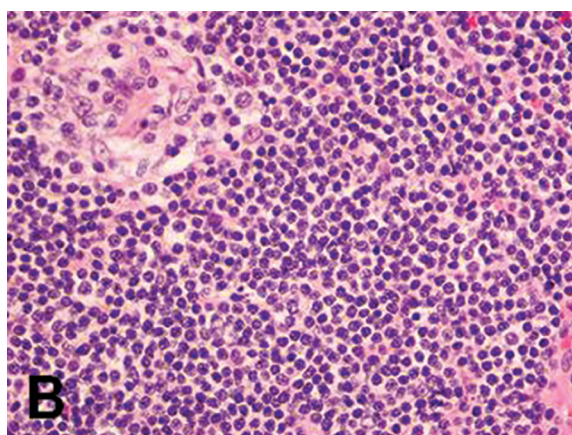
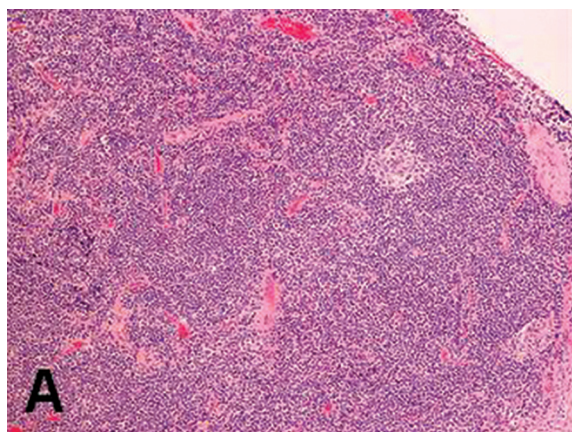
Her cholecystectomy was delayed due to an abnormal screening colonoscopy that was remarkable for a rectal mass which proved to be consistent with an adenocarcinoma on biopsy. She ultimately underwent treatment with chemoradiation followed by a surgical resection of her adenocarcinoma of the rectum without major complication.

Following the rectal cancer treatment, she continued to complain of persistent abdominal pain localized to the right upper quadrant, and therefore underwent her previously planned laparoscopic cholecystectomy without complication. Histopathology from her surgically removed gallbladder was consistent with a primary MALT lymphoma. She underwent further lymphoma staging including an esophagogastroduodenoscopy (EGD), computed tomography scans of the body and a bone marrow biopsy - all of which revealed no evidence of lymphoma.

## Pathologic findings

Grossly, the gallbladder measured 9.6cm in length and 2.5cm in diameter. The serosal surface was smooth with foci of hemorrhage, and sectioning revealed prominent cholesterosis. The fundic wall measured 0.2cm in thickness. There were no stones present in the lumen.

Microscopic examination revealed a dense lymphoid infiltrate that was composed of small cells with a small amount of cytoplasm, round to slightly irregular nuclei, clumped chromatin and inconspicuous nucleoli (Fig. 1). Occasional monocytoid cells were seen. No lymphoepithelial lesion was present.



**Fig 1.** Marginal zone B-cell lymphoma (MALT lymphoma) of the gallbladder

A. A dense lymphoid infiltrate composed of small lymphoid cells expanding the marginal zone of lymphoid follicles. A remnant germinal center is indicated with an arrow (H&E, 100x). B. The neoplastic cells are small with small amount of cytoplasm, round to slightly irregular nuclei, condensed chromatin (H&E, 400x). No mitotic figures are seen. C. The neoplastic cells are positive for CD20 (Immunoperoxidase stain, 400x).

Paraffin immunoperoxidase stains demonstrated these lymphoid cells to be strongly positive for CD20, CD79a, CD43 and BCL-2. The cells were negative for CD5, CD10, CD23 and cyclin D-1. Molecular studies performed on the paraffin block revealed the presence of monoclonal VDJ rearrangement and TCR-gamma rearrangement, further supporting the diagnosis of MALT lymphoma.

## Discussion

MALT lymphomas were initially reported by Isaacson and Wright when describing a particular type of B cell lymphoma that arose from the gastrointestinal tract, and exhibited a distinct histopathologic characteristic. Three main components make up the histological pattern; 1) centrocyte-like cells, 2) small lymphoid cells, and 3) plasma cells [7, 8]. All of the morphological features diagnostic for MALT lymphoma were seen in this case.

Sixteen cases of primary NHL of the gallbladder have been previously described in the English medical literature [6, 9-22]. Of those 16, six cases were primary MALT lymphomas of the gallbladder.

MALT lymphoma represents 38% of all reported primary gallbladder lymphomas, which make it the most frequently reported NHL subtype for this location (Table 1) [6, 10-14].

The prognosis of patients with MALT lymphoma of the gallbladder is excellent when compared to other NHLs of the gallbladder [9,13]. All patients were reported to be alive at the time of publication. Excellent local control was achieved with surgical resection with no local recurrences reported. There was one distant recurrence in the stomach five years after surgical resection which was treated initially with chlorambucil. That patient ultimately achieved a complete remission after 6 courses of fludarabine, mitoxantrone and dexamethasone [15].

With regard to the etiology of MALT lymphomas involving the gallbladder, it is important to note that the gallbladder is normally devoid of lymphoid tissue. It has been hypothesized that lymphomas may occur secondary to chronic cholecystitis or bacterial infection which causes lymphocytes to migrate to the gallbladder mucosa and results in the formation of secondary follicles. The formation of a MALT lymphoma may be secondary to a continuous antigenic stimulus causing a chromosomal translocation which results in a fusion protein that inhibits apoptosis and causes antigen-independent proliferation [13, 23-25]. This transformation, specific for MALT lymphomas, has been proposed for other sites normally devoid of lymphoid tissue, such as the stomach [26, 27].

**In conclusion,** primary MALT lymphomas of the gallbladder are an extremely rare presentation of extranodal NHL. Although the lymphomas are usually found incidentally, patients should undergo a complete staging workup and be monitored for recurrence. In the majority of cases where the lesion is localized to the gallbladder, cholecystectomy alone is considered curative and conveys an excellent prognosis.

**Table I.** Reported cases of primary MALT lymphoma of the gallbladder

Author	Age/Sex	Symptoms	Surgical Procedure and Findings	Histology	Post Surgical Treatment	Outcome
Mosnier 1992	60F	RUQ pain, fever, nausea and vomiting	Cholecystectomy and lymphadenectomy: Dilated gallbladder. Enlarged lymph nodes at gallbladder neck and porta hepatis.	Low grade MALT lymphoma. Chronic follicular cholecystitis, gallstones.	Normal EGD	NED at 6 months.
McCluggage 1996	75F	RUQ pain nausea and vomiting for one month.	Cholecystectomy: a 2cm mass present in the gallbladder	Low grade MALT and Chronic Follicular Cholecystitis	Normal EGD and bone marrow biopsy	NED at 12 months
Bickel 1999	74F	RUQ pain and nausea for one month	Cholecystectomy and right hemi-colectomy: solid mass involving gallbladder and transverse colon	Low grade B cell MALT lymphoma, and gallbladder	Normal EGD and bone marrow biopsy	Not reported
Tsuchiya 2001	58F	Epigastric pain and vomiting	Cholecystectomy: multiple polypoids on gallbladder mucosa	Low grade B cell MALT lymphoma	None	NED at 24 months
Chim 2002	65F	RUQ pain	Cholecystectomy: enlarged gallbladder	Low grade MALT lymphoma	Recurrence at 5 yrs, Tx with chemotherapy	Alive at 8 years
Rajesh 2003	31F	RUQ pain for 6 months	Cholecystectomy and lymphadenectomy: gallbladder wall thickening and portahepatic lymphadenopathy	Low-grade MALT and chronic cholecystitis	Normal bone marrow biopsy	Not reported
Present case	70F	RUQ pain for one year	Cholecystectomy: multiple gallbladder stones	Low-grade MALT, hemorrhagic mucosa and prominent cholesterosis.	Normal EGD and bone marrow biopsy	NED at 2 months

EGD: esophagogastroduodenoscopy; NED: no evidence of disease

## References

1. Van Slyck EJ, Schuman BM. Lymphocytic lymphosarcoma of the gallbladder. *Cancer* 1972; 30: 810-816.
2. Jelic TM, Barreta TM, Yu M, et al. Primary, extranodal, follicular non-Hodgkin lymphoma of the gallbladder: case report and a review of the literature. *Leuk Lymphoma* 2004; 45: 381-387.
3. A clinical evaluation of the International Lymphoma Study Group classification of non-Hodgkin's lymphoma. The Non-Hodgkin's Lymphoma Classification Project. *Blood* 1997; 89: 3909-3918.
4. Isaacson P, Wright DH. Extranodal malignant lymphoma arising from mucosa-associated lymphoid tissue. *Cancer* 1984; 53: 2515-2524.
5. Isaacson P, Wright DH. Malignant lymphoma of mucosa-associated lymphoid tissue. A distinctive type of B-cell lymphoma. *Cancer* 1983; 52: 1410-1416.
6. Pelstring RJ, Essell JH, Kurtin PJ, Cohen AR, Banks PM. Diversity of organ site involvement among malignant lymphomas of mucosa-associated tissues. *Am J Clin Pathol* 1991; 96: 738-745.
7. Isaacson PG, Spencer J. Malignant lymphoma of mucosa-associated lymphoid tissue. *Histopathology* 1987; 11: 445-462.
8. Chan JK. Gastrointestinal lymphomas: an overview with emphasis on new findings and diagnostic problems. *Semin Diagn Pathol* 1996; 13: 260-296.
9. Mosnier JF, Brousse N, Sevestre C, et al. Primary low-grade B-cell lymphoma of the mucosa-associated lymphoid tissue arising in the gallbladder. *Histopathology* 1992; 20: 273-275.
10. McCluggage WG, Mackel E, McCusker G. Primary low grade malignant lymphoma of mucosa-associated lymphoid tissue of gallbladder. *Histopathology* 1996; 29: 285-287.
11. Bickel A, Eitan A, Tsilman B, Cohen HI. Low-grade B cell lymphoma of mucosa-associated lymphoid tissue (MALT) arising in the gallbladder. *Hepatogastroenterology* 1999; 46: 1643-1646.
12. Tsuchiya T, Shimokawa I, Higami Y, et al. Primary low-grade MALT lymphoma of the gallbladder. *Pathol Int* 2001; 51: 965-969.
13. Chim CS, Liang R, Loong F, Chung LP. Primary mucosa-associated lymphoid tissue lymphoma of the gallbladder. *Am J Med* 2002; 112: 505-507.
14. Mitropoulos FA, Angelopoulou MK, Siakantaris MP, et al. Primary non-Hodgkin's lymphoma of the gall bladder. *Leuk Lymphoma* 2000; 40: 123-131.
15. Yasuma T, Yanaka M. Primary sarcoma of the gallbladder--report of three cases. *Acta Pathol Jpn* 1971; 21: 285-304.
16. Vaittinen E. Sarcoma of the gall-bladder. *Ann Chir Gynaecol Fenn* 1972; 61: 185-189.

17. Botha JB, Kahn LB. Primary lymphoma of the gall bladder. Case report and review of the literature. *S Afr Med J* 1974; 48: 1345-1348.
18. Laurino L, Melato M. Malignant angioendotheliomatosis (Angiotropic lymphoma) of the gallbladder. *Virchows Arch A Pathol Anat Histopathol* 1990; 417: 243-246.
19. Friedman EP, Lazda E, Grant D, Davis J. Primary lymphoma of the gallbladder. *Postgrad Med J* 1993; 69: 585-587.
20. Chatila R, Fiedler PN, Vender RJ. Primary lymphoma of the gallbladder; case report and review of the literature. *Am J Gastroenterol* 1996; 91: 2242-2244.
21. Ferluga D, Luzar B, Gadzijev EM. Follicular lymphoma of the gallbladder and extrahepatic bile ducts. *Virchows Arch* 2003; 442: 136-140.
22. Levine EG, Bloomfield CD. Cytogenetics of non-Hodgkin's lymphoma. *J Natl Cancer Inst Monogr* 1990; (10): 7-12.
23. Levine EG, Arthur DC, Machnicki J, et al. Four new recurring translocations in non-Hodgkin lymphoma. *Blood* 1989; 74: 1796-1800.
24. Dierlamm J, Baens M, Wlodarska I, et al. The apoptosis inhibitor gene API2 and a novel 18q gene, MLT, are recurrently rearranged in the t(11;18)(q21;q21) associated with mucosa-associated lymphoid tissue lymphomas. *Blood* 1999; 93: 3601-3609.
25. Wotherspoon AC, Doglioni C, Diss TC, et al. Regression of primary low-grade B-cell gastric lymphoma of mucosa-associated lymphoid tissue type after eradication of *Helicobacter pylori*. *Lancet* 1993; 342: 575-577.
26. Wotherspoon AC, Ortiz-Hidalgo C, Falzon MR, Isaacson PG. *Helicobacter pylori*-associated gastritis and primary B-cell gastric lymphoma. *Lancet* 1991; 338: 1175-1176.