

# Polypoid Vascular and Lymphatic Malformation of the Duodenum: a Case Report

Jeong Wook Kim<sup>1</sup>, Hyoung Chul Oh<sup>1</sup>, Mi Kyung Kim<sup>2</sup>, Jae Gyu Kim<sup>1</sup>

1) Department of Internal Medicine; 2) Department of Pathology, Chung-Ang University College of Medicine, Seoul, Republic of Korea

## Abstract

Polypoid vascular and lymphatic malformation of the small intestine is rare. We report the case of a polypoid vascular and lymphatic malformation of the duodenum in a 58-year-old woman presenting with post-prandial epigastric discomfort. She did not have common symptoms of intestinal vascular and lymphatic malformation, such as gastrointestinal bleeding, steatorrhea, and hypoalbuminemia. A 5.0 x 0.8-cm semipedunculated polypoid lesion was found in the duodenal bulb with protrusion into the prepyloric antrum and was successfully removed using an endoscopic snare

## Keywords

Vascular malformation – lymphatic abnormalities – duodenum – duodenal polyp – endoscopic polypectomy.

## Introduction

Vascular and lymphatic malformation of the small intestine is rare. Generally, vascular malformation appears as a flat or elevated lesion and as a large, bright red submucosal lesion on endoscopy [1]. Lymphatic malformation appears as whitish spots or specks, and yellowish white mucosal or submucosal nodules are found on endoscopy [2]. Polypoid shape is extremely rare in patients with gastrointestinal vascular and lymphatic malformation. We recently encountered a case of a polypoid vascular and lymphatic malformation of the duodenum in a 58-year-old patient. The duodenal vascular and lymphatic malformation was successfully removed using an endoscopic snare.

## Case report

A 58-year-old woman presented with postprandial epigastric discomfort for the past 6 months. She was not taking any medication and had no history of gastrointestinal bleeding. Family history was unremarkable. Her vital signs were stable; laboratory tests revealed a leukocyte count of 6,730/mm<sup>3</sup>; hemoglobin, 14.1 g/dL; and platelet count, 219,000/mm<sup>3</sup>. The electrolytes, coagulation test, and liver function tests, including serum protein and albumin level, were normal. Esophagogastroduodenoscopy revealed a 5.0 × 0.8-cm semi-pedunculated polypoid lesion in the duodenal bulb with protrusion into the prepyloric antrum (Fig. 1). The endoscopic ultrasonographic examination proved unsuccessful because of poor patient cooperation during the procedure. Colonoscopy and dynamic abdominal computed tomography (CT) revealed no abnormality. Mucosal biopsy findings of the duodenal polypoid lesion showed normal duodenal epithelium. Medical treatment failed to relieve her symptoms, and it was decided that epigastric discomfort was due to the duodenal polypoid lesion.

The duodenal polypoid lesion was removed using an endoscopic snare (SD-9L-1; Olympus Optical Co., Ltd., Tokyo, Japan) electrocautery after submucosal injection of hypertonic saline-epinephrine solution. To prevent bleeding and achieve hemostasis from the polypectomy site, hemostatic clips (HX-610; Olympus) were applied to the ulcer induced by polypectomy (Fig. 2). Microscopic examination showed ectatic blood vessels and lymphatics in the dilated submucosal space with intact mucosal surfaces (Fig. 3). During the 1-year follow-up, there were no signs of bleeding or epigastric discomfort. Esophagogastroduodenoscopy showed scar formation resulting from prior endoscopic removal (Fig. 4).

## Discussion

Vascular malformations of the gastrointestinal tract may be asymptomatic and present with bleeding or anemia. These lesions usually occur as a small solitary lesion such as angiodysplasia and are grossly visible as a large submucosal

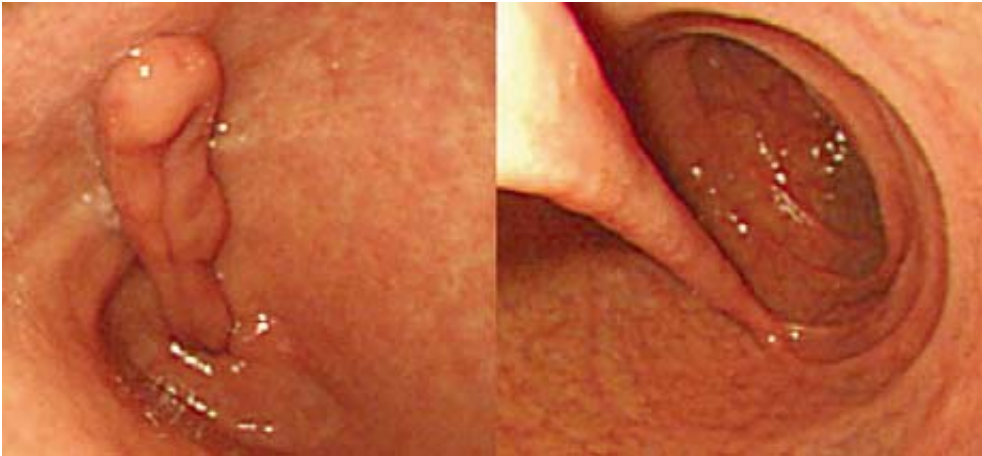Received: 11.02.2009 Accepted: 13.02.2009

J Gastrointest Liver Dis

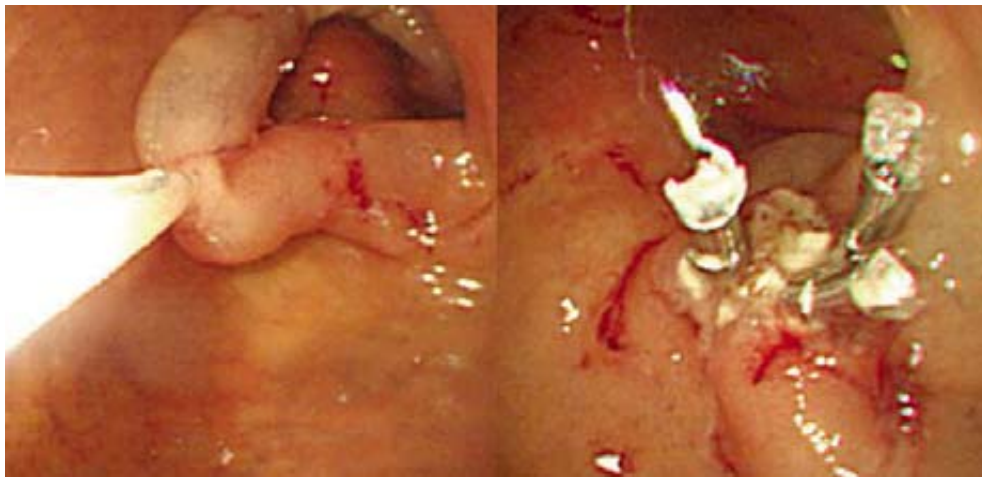
March 2010 Vol.19 No 1, 85-87

Address for correspondence:

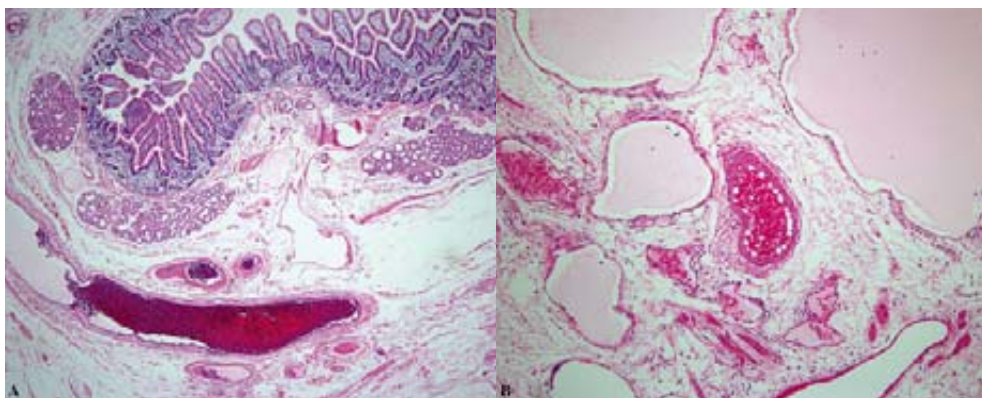
Jeong Wook Kim  
Department of Internal Medicine  
Chung-Ang University  
College of Medicine  
Seoul, Republic of Korea  
E-mail: ekg001@cau.ac.kr



**Fig 1.** Endoscopic view of a semipedunculated polypoid lesion with protrusion to prepyloric antrum in the duodenal bulb.



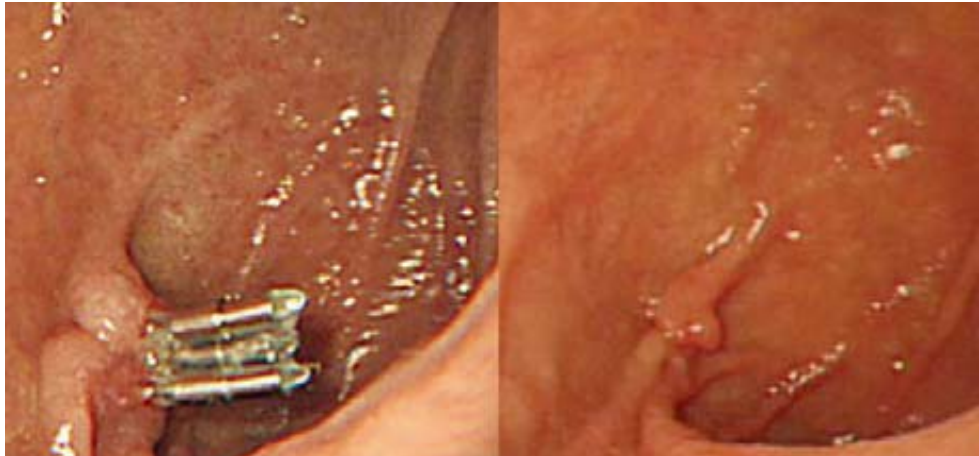**Fig 2.** Endoscopic removal of the duodenal polypoid lesion by a snare after submucosal injection of hypertonic saline-epinephrine solution and application of hemostatic clips to the polypectomy-induced ulcer.



**Fig 3.** A. Low-power photomicrograph of the polypectomy specimen with variable-sized, abnormal submucosal spaces with intact overlying mucosa (H-E $\times$ 100). B. Ectatic vessels and lymphatics in the dilated submucosal spaces (H-E  $\times$ 200).

vessel that is thought to be congenital in origin [1]. These are aberrations in the normal vascular architecture, affecting arterial, venous, capillary, and sometimes, lymphatic vessels.

Polypoid vascular malformations are rare in the small intestine, and only four cases have been reported to date (Table I) [3–5]. All four patients reported previously were over 40 years old, and there was no gender preference.



**Fig 4.** Scar of the previous mucosal resection site on follow-up endoscopy after 1 month (left) and 1 year (right).

**Table I.** Summary of reported polypoid vascular malformations of the small intestine

	Eastman et al [3]	Averbach et al [4]	Averbach et al [4]	Palma et al [5]	Present case
Age(years)/gender	41/male	46/female	80/male	56/male	48/female
Chief complaint	Hematochezia	Iron deficiency anemia	Dizziness, melena	Obscure GI bleeding	Epigastric discomfort
Location	Jejunum	Terminal ileum	Duodenal, third portion	Ileum	Duodenal bulb
Maximal diameter (cm)		0.4	0.8	3.5	5.0
Gross finding	Sessile	Sessile	Sessile	Sessile	Semipedunculated
Histologic finding	Arteriovenous malformation	Vascular ectasia	Arteriovenous malformation	Vascular ectasia	Vascular and lymphatic ectasia
Treatment	Surgery	Surgery	Snare polypectomy	Surgery	Snare polypectomy
Result	Hemostasis	Improvement of anemia	Hemostasis	Hemostasis	Improvement of symptom

Gastrointestinal bleeding was noted in all four cases. The lesions occurred over the entire small intestine and measured 0.4 to 3.5 cm in diameter. All the reported cases, except our case, were sessile in form and did not appear grossly vascular. The lesion was diagnosed by snare polypectomy, and surgery was performed to control gastrointestinal bleeding. Benign vascular proliferations of the gastrointestinal tract include sporadic vascular ectasias and arteriovenous malformations, which present with distinctive histologic features. Vascular ectasias consist of ectatic veins, venules, and capillaries within the mucosa and submucosa but do not involve muscularis propria. However, true arteriovenous malformations contain true arteries or arterioles and involve the entire bowel wall, including the muscularis propria. Two cases of ileal polypoid vascular malformation had histologic features of vascular ectasia. In the remaining two cases, duodenal and jejunal lesions showed arteriovenous malformations.

Intestinal lymphatic malformation such as lymphangiectasia is due to obstruction of the lymph drainage system into the intestinal villi in the lamina propria and submucosa of the small bowel as well as on the serosal surface

of the mesentery. Malformation of the lymphatic system may be congenital or acquired. Congenital cases are due to a deformity of the lymphatic system, while acquired cases are caused by the defect secondary to retroperitoneal fibrosis, pancreatitis, neoplasm, and infiltrative disorders that block the lymphatics [6]. Intestinal lymphatic malformation may be asymptomatic and present with steatorrhea, malabsorption, lymphocytopenia, hypoalbuminemia, chylous ascites, and chylous pleural effusions. Dilated lacteals of the intestine can be seen as diffuse white spots or white-tipped villi sometimes associated with white nodular lesions [2, 6, 7]. However, polypoid lymphatic malformation of the small intestine has not yet been reported.

Polyps of the duodenal bulb include a variety of pathologic types, including heterotopic gastric mucosa, cyst formation, duodenitis, Brunner's gland hyperplasia, adenoma, and carcinoma. Pedunculated polyps of the duodenal bulb are histological features of adenoma and Brunner's gland adenoma [8, 9].

In the present case, the endoscopic findings showed a long polypoid lesion on the duodenal bulb, and dynamic CT did not show any vascular or lymphatic malformations.

The patient did not have common clinical manifestations associated with vascular and lymphatic malformations of the intestine. Since the lesion did not reveal any vascularity during endoscopic removal, additional studies such as conventional angiography and CT angiography for defining the submucosal extension of the malformations were not conducted [4]. The lesion was endoscopically removed with a snare electrocautery and vascular clipping without any complications such as intestinal bleeding. Pathologic examination showed submucosal ectatic blood vessels and lymphatics.

In **conclusion**, the present case is the first case of duodenal polypoid vascular and lymphatic malformations in the small intestine without the commonly associated clinical manifestations. Endoscopists should consider the diagnosis in a patient presenting with a polypoid lesion of the duodenum, demonstrate the vascular nature, and then choose an appropriate therapy.

## References

1. Moore JD, Thompson NW, Appelman HD, Foley D. Arteriovenous malformations of the gastrointestinal tract. *Arch Surg* 1976; 111: 381-389.
2. Aoyagi K, Iida M, Yao T, et al. Characteristic endoscopic features of intestinal lymphangiectasia: correlation with histological findings. *Hepatogastroenterology* 1997; 44: 133-138.
3. Eastman J, Nazek M, Mangels D. Localized arteriovenous malformation of the jejunum. *Arch Pathol Lab Med* 1994; 118: 181-183.
4. Averbach M, Marques OW Jr, Correa PA, Cappellanes CA, Hashiba K. Small-bowel angiodysplasia and intestinal bleeding: a diagnostic challenge. *Gastrointest Endosc* 2006; 64: 1008.
5. Palma GD, Aprea G, Rega M, et. al. Polypoid vascular malformation of the small intestine. *Gastrointest Endosc* 2007; 65: 328-329.
6. Fang YH, Zhang BL, Wu JG, Chen CX. A primary intestinal lymphangiectasia patient diagnosed by capsule endoscopy and confirmed at surgery: a case report. *World J Gastroenterol* 2007; 13: 2263-2265.
7. Chamouard P, Nehme-Schuster H, Simler JM, Finck G, Baumann R, Pasquali JL. Videocapsule endoscopy is useful for the diagnosis of intestinal lymphangiectasia. *Dig Liver Dis* 2006; 38: 699-703.
8. Matsui K, Kitagawa M. Biopsy study of polyps in the duodenal bulb. *Am J Gastroenterol* 1993; 88: 253-257.
9. Matsuura H, Kuwano H, Kanematsu T, Sugimachi K, Haraguchi Y. Clinicopathological features of elevated lesions of the duodenal bulb. *J Surg Oncol* 1990; 45: 79-84.