

NSAID-induced Colopathy. A Case Series

Abdur R Aftab, Fergal Donnellan, Faisal Zeb, David Kevans, Garret Cullen, Garry Courtney

St. Luke's Hospital, Kilkenny, Ireland

Abstract

The adverse effects of non-steroidal anti-inflammatory drugs (NSAIDs) on the upper gastrointestinal tract and small intestine are well established. The effect of such therapy on the large intestine, so called NSAID colopathy, is less well described. We present four such cases demonstrating the characteristic endoscopic findings. One case in particular is, to our knowledge, the first report of the natural history of this clinical entity, initially presenting with the acute picture of inflammation and ulceration with subsequent progression to the more chronic development of diaphragm-like fibrous strictures. NSAID-induced colonic damage is a clinically significant condition. Two of our patients presented with bloody diarrhoea while the other two patients developed symptomatic anaemia. With the increasing use of enteric coated and sustained release NSAID preparations this condition is likely to become more frequent. Increasing awareness of its clinical presentation and of its spectrum of endoscopic findings facilitates a more prompt diagnosis and appropriate treatment to be established.

Key words

NSAID – colopathy – anemia – lower digestive hemorrhage – colon stricture.

Introduction

Debenham described the first case of NSAID-induced colonic damage in 1966, highlighting a case of caecal ulceration in a patient taking oxyphenbutazone for rheumatoid arthritis [1]. Since then, the association between NSAIDs and colonic damage has become well established,

albeit less well recognized than NSAID-induced gastropathy and enteropathy. Isolated case reports of NSAID colopathy range from the more acute complication of inflammation and ulceration to the more chronic picture of fibrosis and stricture formation.

Case 1

The first case involves a 65 year old woman who presented with a year long history of bloody diarrhoea with intermittent nausea and vomiting and iron deficiency

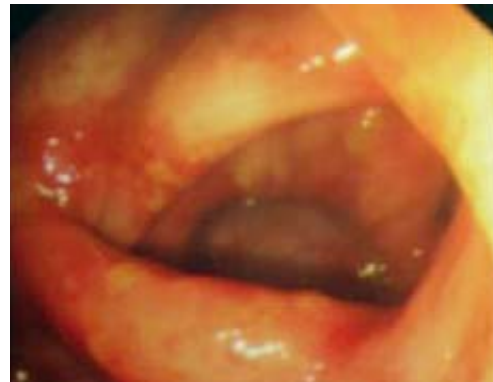


Fig 1. Finding at colonoscopy showing right sided patchy inflammation.

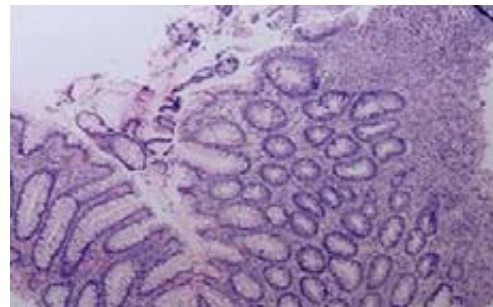


Fig 2. Relatively normal colonic mucosa with adjacent area of ulceration with acute colitis and glandular distortion. There are no granulomas, epithelial dysplasia or malignancy (H-E x 40).

Received: 16.02.2009 Accepted: 26.02.2009

J Gastrointest Liver Dis

March 2010 Vol. 19 No 1, 89-91

Address for correspondence:

Dr. AR Aftab
Department of Gastroenterology
St. Luke's Hospital
Kilkenny, Ireland
E-mail: aftabar@hotmail.com

anaemia with a haemoglobin of 9.8g/dL (12 - 15.0g/dL) and a mean corpuscular volume of 68 (83 - 100). Her past medical history was significant for seronegative arthritis for which she was taking diclofenac 75mg twice daily for one year prior to presentation. Upper gastrointestinal endoscopy showed *Helicobacter pylori* negative antral gastritis. Small bowel biopsies were normal. A colonoscopy showed moderate patchy inflammation from the sigmoid colon to the caecum (Fig. 1). Subsequent biopsies revealed mild cryptitis in the ascending and descending colon. There was no evidence of goblet cell depletion, crypt abscess formation, granulomata or malignancy (Fig. 2). The terminal ileum was normal at endoscopy and subsequent biopsies were unremarkable. The patient was treated for an acute exacerbation of inflammatory bowel disease and her symptoms settled initially on intravenous and subsequently oral steroids. Of note, the patient remained on diclofenac therapy. However, seven months later, while on 5mg prednisolone, she presented again with diarrhoea and a haemoglobin of 5.5g/dl. A second gastroscopy was unremarkable and repeat colonoscopy

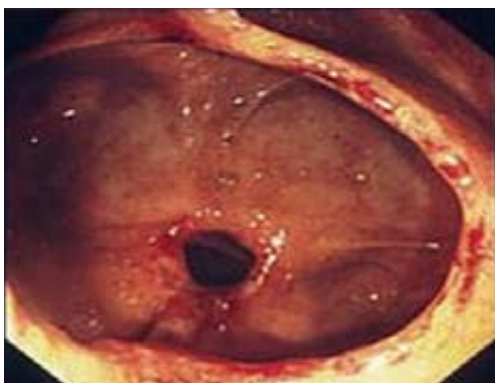


Fig 3. Finding at 2nd colonoscopy of right-sided diaphragm-like stricture with associated inflammation.

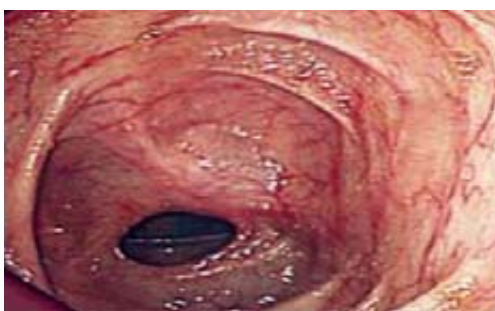

Fig 4. Finding at 3rd colonoscopy of right-sided diaphragm without any associated inflammation.

revealed multiple diaphragm-like strictures associated with patchy inflammation from the splenic flexure to caecum (Fig. 3). Interestingly serial colonic biopsies were unremarkable. It was felt at this stage that the clinical picture was more in keeping with NSAID-induced colonic damage rather than inflammatory bowel disease.

The likely offending agent was stopped. She did not receive any further steroid therapy. The diarrhoea

subsequently settled. A third colonoscopy performed one year after the initial presentation showed a number of fibrous diaphragms situated in the right colon. There was not any associated inflammation and again the biopsies were normal (Fig. 4). The patient has remained symptom-free with normal haemoglobin 18 months after her last colonoscopy.

Case 2

The second case involves a 63 year old woman who presented with iron deficiency anaemia. Her haemoglobin measured 4.1g/dL and mean corpuscular volume was 64. She had noticed increasing dyspnoea and fatigue over the preceding three months. She did not have any gastrointestinal symptoms. Her past medical history was significant for osteoarthritis for which she was taking diclofenac 50mg daily for two years prior to presentation. Gastroscopy was unremarkable apart from a mild *Helicobacter pylori* negative antral gastritis. Biopsies from the proximal small bowel were negative for coeliac disease. Subsequent colonoscopy was performed to the terminal ileum. While patchy inflammation was evident throughout the colon, the most predominant feature was six fibrous diaphragms in the right colon. The terminal ileum was normal. Subsequent biopsies from the fibrous diaphragms were unremarkable. Eighteen months later, off diclofenac, she remains well with normal haemoglobin.

Case 3

The third case was a 57 year old woman with iron deficiency anaemia. Her haemoglobin was 7.4g/dL with a mean corpuscular volume of 76. She suffered from Still's disease for which she had been taking diclofenac 75mg twice daily for two months prior to admission and prednisolone 5mg daily. Her past medical history also included hypertension. The patient did not have any gastrointestinal symptoms. Upper endoscopy was performed showing mild *Helicobacter pylori* negative antral gastritis. A colonoscopy was also carried out. This demonstrated two separate areas of inflamed ulcerated mucosa with early stricture formation in the right colon. In addition there was mild inflammation present in the left colon. While both malignancy and Crohn's disease were considered in the differential diagnosis, it was felt that the overall picture was more consistent with NSAID-induced colopathy. Subsequent biopsies from the right colon revealed densely inflamed granulation tissue consistent with ulceration. There was no evidence of active colitis, dysplasia or malignancy. The patient's diclofenac medication has since been stopped and twelve months later she remains well with normal haemoglobin.

Case 4

A 61 year old woman was referred by her G.P. with four months history of intermittent bloody diarrhoea and anaemia. Her haemoglobin was 7.2 g/dL with mean corpuscular volume of 72. She had a background history of rheumatoid

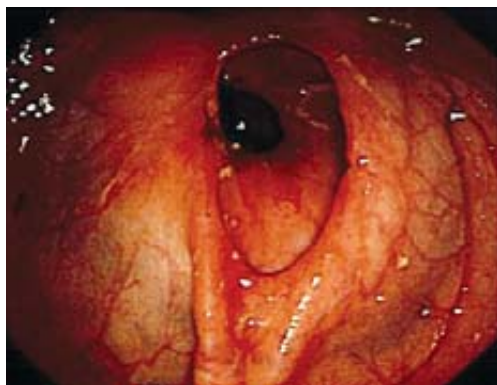


Fig 5. Inflamed diaphragm in ascending colon seen at colonoscopy (Case 4).

arthritis, hypertension, osteoporosis, fibromyalgia and depression. She had been taking diclofenac 75 mg twice daily for five years, prednisolone 5 mg daily and methotrexate for R.A. and fosmax for osteoporosis. As part of the investigation for bloody diarrhoea a colonoscopy was performed which showed several inflammatory diaphragms from the transverse colon to caecum (Fig. 5). The terminal ileum appeared normal. Biopsies were taken from ascending and transverse colon diaphragms which showed ulceration with a formation of sub acute fibro-vascular granulation tissue. There was no evidence of granulomata, cryptitis or dysplasia. Random left colonic biopsies were normal. The diclofenac has since been stopped and six months later the patient remains well.

Discussion

We would like to highlight our case series for a number of reasons. Firstly, the endoscopic findings were confined predominantly to the right colon. This is in keeping with previous reports supporting the theory that this condition occurs as a result of direct drug toxicity. The increasing use of both slow release and enteric coated preparations allow more of the medication to reach the right colon with the caecum acting as a reservoir [2, 3].

NSAID-induced colonic damage is clinically significant and not just a benign endoscopic finding. The four patients presented with symptoms ranging from debilitating bloody diarrhoea to symptomatic anaemia requiring blood transfusion. Reports in the literature also indicate that the NSAID-induced fibrous diaphragms can lead to significant stenoses necessitating balloon dilatation and often segmental colectomy [4, 5].

Our series highlights that this effect of NSAIDs is not likely to be dose related. Our patients were taking doses between 50 mg to 150mg daily. However the duration of treatment is highly significant demonstrating a temporal

relationship between drug administration and the spectrum of endoscopic features found in NSAID colopathy.

The patient described in Case 3 was on treatment for two months and showed evidence only of colonic inflammation and ulceration that at endoscopy could be mistaken for Crohn's disease or colonic malignancy. The patients described in Cases 1, 2 and 4 were on treatment with diclofenac for a number of years and consequently demonstrated the more pathognomonic feature of diaphragm-like colonic strictures [6, 7]. To our knowledge the natural history of NSAID colopathy has not been described. Interestingly, the patient described in Case 1 had a series of colonoscopies which demonstrated endoscopic evidence of progression of this condition. Inflammation was evident at the initial colonoscopy one year into treatment with diclofenac. This progressed over the next seven months to early diaphragm formation associated with the initial inflammatory changes. The patient had remained on NSAID treatment during this time. Cessation of the drug resulted in resolution of the inflammation. However, the diaphragms already formed, persisted.

Increasing awareness of this clinical phenomenon of NSAID-induced colopathy allows a prompt endoscopic diagnosis to be made instead of other differential diagnoses such as inflammatory bowel disease or colon cancer. This would lead to the appropriate management and cessation of the offending agent, thereby avoiding potential toxic effects of other treatments.

Conflicts of interest

None to declare.

References

1. Debenham GP. Ulcer of the cecum during oxyphenbutazone (tandearil) therapy. *Can Med Assoc J* 1966 28; 94:1182-1184
2. Byrne MF, McGuinness J, Smyth CM, et al. Nonsteroidal anti-inflammatory drug-induced diaphragms and ulceration in the colon. *Eur J Gastroenterol Hepatol* 2002;14: 1265-1269.
3. Aloysius MM, Kaye PV, Lobo DN. Non-steroidal anti-inflammatory drug (NSAID)-induced colonic strictures and perforation: a case report. *Dig Liver Dis* 2006; 38: 276-278.
4. Gopal DV, Katon RM. Endoscopic balloon dilation of multiple NSAID-induced colonic strictures: case report and review of literature on NSAID-related colopathy. *Gastrointest Endosc* 1999; 50: 120-123.
5. Smith JA, Pineau BC. Endoscopic therapy of NSAID-induced colonic diaphragm disease: two cases and a review of published reports. *Gastrointest Endosc* 2000; 52: 120-125.
6. Huber T, Ruchti C, Halter F. Nonsteroidal antiinflammatory drug-induced colonic strictures: a case report. *Gastroenterology* 1991;100:1119-1122.
7. Israel LH, Koea JB, Stewart ID, Wright CL, Frankish PD. Nonsteroidal anti-inflammatory drug-induced strictures of the colon: report of a case and review of the literature. *Dis Colon Rectum* 2001; 44:1362-1364.