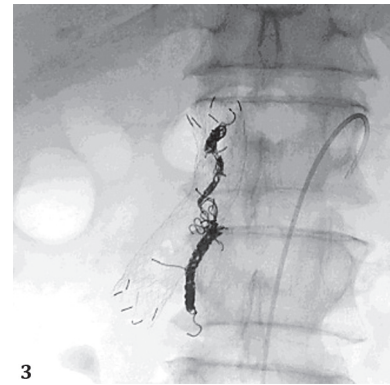
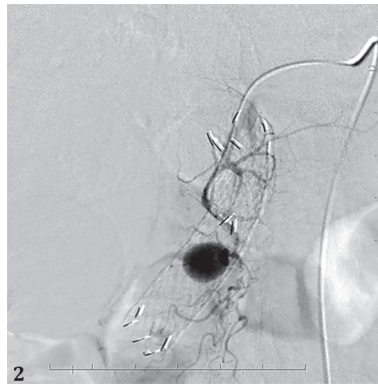
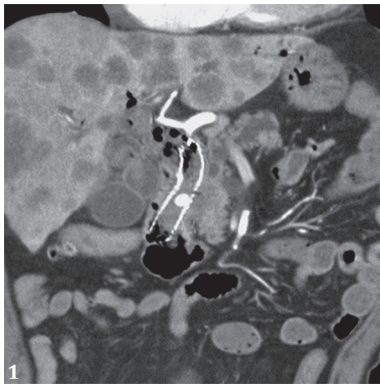
Posterior Superior Pancreaticoduodenal Artery Pseudoaneurysm Caused by a Large-bore Biliary Metal Stent

Kazunari Nakahara, Junya Sato, Keisuke Tateishi

Department of Gastroenterology, St. Marianna University, School of Medicine, Sugao, Miyamae-ku, Kawasaki, Japan



A 73-year old man, who received chemotherapy after a fully covered metal stent (CMS) placement for distal biliary stricture due to pancreatic cancer, presented with obstructive jaundice because of stent dislodgement. Therefore, endoscopic retrograde cholangiopancreatography was performed, and a 14-mm large-bore uncovered metal stent (UCMS) (Niti-S 14, Taewoong Medical Co., Ltd., Seoul, South Korea) was placed. However, the patient developed melena 41 days post-stent placement, and blood test revealed a 7.1 g/dl hemoglobin level. Computed tomography showed an 11 mm × 9 mm pseudoaneurysm within the UCMS (Fig. 1). We performed an emergency angiography, and embolized a pseudoaneurysm detected in a posterior superior pancreaticoduodenal artery (PSPDA) branch (Fig. 2) with coils. However, 4 days post-embolization, the melena recurred, and the hemoglobin level decreased to 6.0 g/dl. Hence, we performed a second emergency angiography and an additional coiling (Fig. 3). Thereafter, the patient had no bleeding until his death due to pancreatic cancer 1 month later.

Pseudoaneurysm caused by metal stent is a rare but potentially fatal incident. In most previous reports, hepatic artery pseudoaneurysms occurred due to the contact with the stent's proximal edge [1, 2]. In this case, the pseudoaneurysm was presumably caused by the PSPDA wall necrosis due to compression by the large-bore UCMS. Although there have been reports of tamponade hemostasis using a 10-mm-diameter CMS for pseudoaneurysms [3-5], this procedure is not possible when a 14 mm large-diameter UCMS has been

previously placed, while vascular embolization is useful. In conclusion, endoscopists should bear in mind that large-bore UCMSs can cause PSPDA pseudoaneurysm.

Corresponding author: Kazunari Nakahara, nakahara@marianna-u.ac.jp

Conflicts of interest: None to declare.

REFERENCES

1. Nezu Y, Nakaji S, Fujii H, Ishii E, Hirata N. Pseudoaneurysm caused by a self-expandable metal stent: a report of three cases. *Endoscopy* 2014;46:248-251. doi:[10.1055/s-0033-1359178](https://doi.org/10.1055/s-0033-1359178)
2. Satoh T, Matsubayashi H, Ishiwatari H, et al. Rupture of Pseudoaneurysm after Biliary Metallic Stent Placement. *Intern Med* 2019;58:1453-1457. doi:[10.2169/internalmedicine.1862-18](https://doi.org/10.2169/internalmedicine.1862-18)
3. Tonozuka R, Itoi T, Sofuni A, Itokawa F, Ishii K. Hemostasis using a fully covered self-expandable metal stent for marked bleeding from the bile duct following stent removal (with videos). *J Hepatobiliary Pancreat Sci* 2013;20:254-256. doi:[10.1007/s00534-012-0516-8](https://doi.org/10.1007/s00534-012-0516-8)
4. Fujimori N, Matsumoto K, Murakami M, Suehiro Y, Oono T. Endoscopic tamponade using a fully covered self-expandable metallic stent for massive biliary bleeding from a pseudoaneurysm rupture during metallic stent removal. *VideoGIE* 2020;6:24-26. doi:[10.1016/j.vgie.2020.08.009](https://doi.org/10.1016/j.vgie.2020.08.009)
5. Soga K, Mazaki M, Kano T. Rupture of a pseudoaneurysm after uncovered self-expanding biliary metallic stent placement. *Dig Endosc* 2022;34:e75-e76. doi:[10.1111/den.14270](https://doi.org/10.1111/den.14270)